

Orthopedic Sports Injuries: Off The Sidelines And Into The Emergency Department

8:50 p.m., Friday night: Paramedics radio ahead—they are bringing in a local high school football player who was tackled during a game. He can't feel or move anything below his legs. The news media are already at the hospital asking questions. The paramedics want to know whether they should start steroids. The on-call neurosurgeon is not answering his pages.

SPORTS injuries present unique challenges to the emergency physician. From the little-leaguer to the cardiac rehabilitation patient, millions of Americans participate in sports or fitness activities. While an athletic injury rarely requires a life- or limb-saving intervention in the ED, the personal impact on the player can be monumental. Emergency physicians must be expert in the diagnosis and initial treatment of sports-related injuries.

Each year in the United States, an estimated 150 million adults participate in some type of non-work-related physical activity, and approximately 30 million children and adolescents participate in organized sports.¹ From July 2000 through June 2001, an estimated 4.3 million sports- and recreation-related injuries were treated in U.S. EDs, comprising 16% of all unintentional injury-related ED visits.¹ The percentage was highest for those 10-14 years old and lowest for those over 45. Among all ages, rates were higher for males than for females.¹ Males are most often injured during playground activities, cycling, football, and basketball. In girls, most injuries are caused by playground activities, basketball, cycling, and general exercise.¹

The most frequent diagnoses include strains/sprains (29.1%), fractures (20.5%), contusions/abrasions (20.1%), and lacerations (13.8%). The body parts most frequently involved are the ankles (12.1%), fingers (9.5%), face (9.2%), head (8.2%), and knees (8.1%). Overall, 2.3% of people with sports- and recreation-related injuries were hospitalized.¹ (See Table 1 on page 2.)

This issue of *Emergency Medicine Practice* describes management strategies for common orthopedic sports injuries. Prior issues of *Emergency Medicine*

April 2003
Volume 5, Number 4

Authors

Lisa Freeman, MD, FACEP

Assistant Residency Director, Department of Emergency Medicine, University of Texas Medical School at Houston, Houston, TX.

Adam Corley, MD

Department of Emergency Medicine, University of Texas Medical School at Houston, Houston, TX.

Peer Reviewers

Mohamud Daya, MD, MS, FACEP, FACMT, DTM&H

Associate Professor of Emergency Medicine, Oregon Health & Science University, Portland, OR.

David Della-Giustina, MD, FACEP

LTC, U.S. Army; Emergency Medicine Consultant to the Surgeon General of the Army; Chairman and Program Director, Madigan Army Medical Center—University of Washington Emergency Medicine Residency; Clinical Assistant Professor of Medicine, University of Washington; Adjunct Assistant Professor of Military and Emergency Medicine, Uniformed Services University, Tacoma, WA.

CME Objectives

Upon completing this article, you should be able to:

1. list conditions or circumstances that require orthopedic or surgical consultation or referral in patients with sports injuries;
2. describe the appropriate treatment and disposition for common orthopedic sports injuries;
3. describe clinical decision rules such as the Ottawa knee rules that are used to determine the need for radiography; and
4. discuss different techniques for shoulder reduction.

Date of original release: April 1, 2003.

Date of most recent review: March 7, 2003.

See "Physician CME Information" on back page.

Editor-in-Chief

Stephen A. Coluccelli, MD, FACEP, Assistant Chair, Department of Emergency Medicine, Carolinas Medical Center, Charlotte, NC; Associate Clinical Professor, Department of Emergency Medicine, University of North Carolina at Chapel Hill, Chapel Hill, NC.

Associate Editor

Andy Jagoda, MD, FACEP, Vice-Chair of Academic Affairs, Department of Emergency Medicine; Residency Program Director; Director, International Studies Program, Mount Sinai School of Medicine, New York, NY.

Editorial Board

Judith C. Brillman, MD, Residency Director, Associate Professor, Department of Emergency Medicine, The University of

New Mexico Health Sciences Center School of Medicine, Albuquerque, NM.

W. Richard Bukata, MD, Clinical Professor, Emergency Medicine, Los Angeles County/USC Medical Center, Los Angeles, CA; Medical Director, Emergency Department, San Gabriel Valley Medical Center, San Gabriel, CA.

Francis M. Fesmire, MD, FACEP, Director, Heart-Stroke Center, Erlanger Medical Center; Assistant Professor of Medicine, UT College of Medicine, Chattanooga, TN.

Valerio Gai, MD, Professor and Chair, Department of Emergency Medicine, University of Turin, Italy.

Michael J. Gerardi, MD, FACEP, Clinical Assistant Professor, Medicine, University of Medicine and Dentistry of New Jersey; Director, Pediatric Emergency Medicine, Children's Medical Center, Atlantic Health System;

Vice-Chairman, Department of Emergency Medicine, Morristown Memorial Hospital.

Michael A. Gibbs, MD, FACEP, Chief, Department of Emergency Medicine, Maine Medical Center, Portland, ME.

Gregory L. Henry, MD, FACEP, CEO, Medical Practice Risk Assessment, Inc., Ann Arbor, MI; Clinical Professor, Department of Emergency Medicine, University of Michigan Medical School, Ann Arbor, MI; President, American Physicians Assurance Society, Ltd., Bridgetown, Barbados, West Indies; Past President, ACEP.

Jerome R. Hoffman, MA, MD, FACEP, Professor of Medicine/Emergency Medicine, UCLA School of Medicine; Attending Physician, UCLA Emergency Medicine Center; Co-Director, The Doctoring Program, UCLA School of Medicine, Los Angeles, CA.

Francis P. Kohrs, MD, MSPH, Associate Professor and Chief of the Division of Family Medicine, Mount Sinai School of Medicine, New York, NY.

John A. Marx, MD, Chair and Chief, Department of Emergency Medicine, Carolinas Medical Center, Charlotte, NC; Clinical Professor, Department of Emergency Medicine, University of North Carolina at Chapel Hill, Chapel Hill, NC.

Michael S. Radeos, MD, MPH, Attending Physician, Department of Emergency Medicine, Lincoln Medical and Mental Health Center, Bronx, NY; Assistant Professor in Emergency Medicine, Weill College of Medicine, Cornell University, New York, NY.

Steven G. Rothrock, MD, FACEP, FAAP, Associate Professor of Emergency Medicine, University of Florida; Orlando Regional Medical Center; Medical Director of Orange County Emergency

Medical Service, Orlando, FL.

Alfred Sacchetti, MD, FACEP, Research Director, Our Lady of Lourdes Medical Center, Camden, NJ; Assistant Clinical Professor of Emergency Medicine, Thomas Jefferson University, Philadelphia, PA.

Corey M. Slovis, MD, FACP, FACEP, Professor of Emergency Medicine and Chairman, Department of Emergency Medicine, Vanderbilt University Medical Center; Medical Director, Metro Nashville EMS, Nashville, TN.

Mark Smith, MD, Chairman, Department of Emergency Medicine, Washington Hospital Center, Washington, DC.

Charles Stewart, MD, FACEP, Colorado Springs, CO.

Thomas E. Terndrup, MD, Professor and Chair, Department of Emergency Medicine, University of Alabama at Birmingham, Birmingham, AL.

Practice, such as the January 2000 issue on mild head trauma, the February 2000 issue on back pain, the October 2001 issue on cervical spine injuries, the November 2001 issue on wrist injuries, and the May 2002 issue on ankle injuries, also provide pertinent information.

“When I played pro football, I never set out to hurt anybody deliberately, unless it was, you know, important, like a league game or something.”—Dick Butkus

Critical Appraisal Of The Literature

Sports medicine, which has long been more of an art, is slowly becoming more of a science. However, few large, randomized, controlled trials provide evidence for many of the treatments used for sports injuries. A recent study attempted to examine the evidence base of sports medicine research. In evaluating four major journals that present core research in sport and exercise medicine, it was noted that randomized, controlled trials comprised 10% or less of all original research articles. Observational/descriptive studies were the most commonly published study design. When good quality research methods (randomized, controlled trials as well as case-control and cohort studies) were categorized together, the difference between sports journals and other medical journals was not significant ($P = 0.09$). This seems to indicate that the quality of sports medicine research is comparable to that in other specialities.²

Well-designed clinical decision rules such as the Ottawa knee and ankle rules are excellent examples of evidence-based medicine. Such rules begin with a derivation set (in these cases, indications for radiography) later confirmed in a prospective validation study.

Prehospital Care

Prehospital care personnel should first ensure adequate airway, breathing, and circulation. Medics should splint suspected fractures before moving the patient and straighten severely angulated fractures. Confirm neurovas-

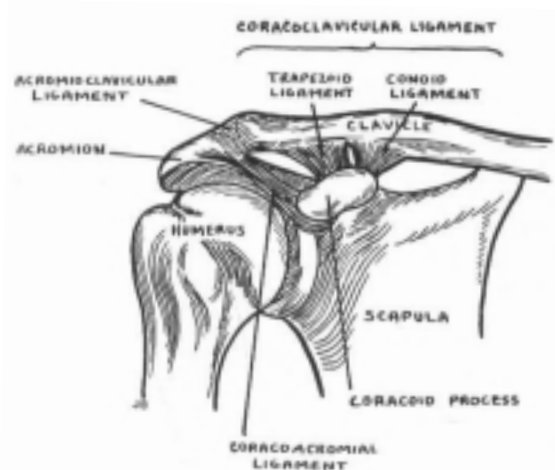
cular status in injured extremities prior to and after splinting. Helmets should be stabilized rather than removed in the field unless the helmet prevents control of a bleeding site or airway management.

Emergency Department Evaluation: Shoulder Injuries

The shoulder is composed of three joints—the glenohumeral (GH), the acromioclavicular (AC), and the sternoclavicular—and one articulation (the scapulothoracic). The GH and AC joints are the most relevant in the practice of sports medicine. The AC joint has a limited range of motion and is stabilized by several ligaments and muscle attachments. (See Figure 1.)

Unlike the AC joint, the GH joint is designed for

Figure 1. Shoulder anatomy.



Schematic representation of the normal ligamentous attachments between the acromion and the coracoid process of the scapula and the clavicle.

Reproduced with permission from: Harris JH Jr, Harris WH. *The Radiology of Emergency Medicine*. 4th ed. Philadelphia: Lippincott, Williams & Wilkins; 2000:304. Figure 9.

Table 1. Sports-Related Injury Sites.

Sport	Injury site (most likely > less likely)
Baseball and softball	shoulder >> elbow/forearm, wrist, fingers > ankle, hip, back
Basketball and volleyball	ankle, knee >> hip/thigh > Achilles tendon, heel, thigh, foot
Football	knee > ankle > head, shoulder, neck > back, face, wrist/fingers
Hockey	head/neck > ankle, knee, shoulder/arm > eye, wrist/hand
Gymnastics	shoulders > torso/back/hip, wrist > elbow > ankle, head/neck
Roller-blading	distal forearm/wrist > lower leg > elbow > knee > head
Snowboarding	wrist > head >> upper extremity > lower extremity
Snow skiing	lower extremity, leg/knee >> head >> thumb, shoulder, ankle
Soccer	knee/ankle >> shin/foot, hip/thigh >> shoulders, cervical spine, head
Swimming	shoulder > knee > elbow, head/spine (diving)
Wrestling	shoulder >> knee >> back/neck, foot/ankle, wrist/hand

Source: Luckstead EF Sr, Satran AL, Patel DR. Sports injury profiles, training and rehabilitation issues in American sports. *Pediatr Clin North Am* 2002 Aug;49(4):753-767.

function and mobility rather than stability. The humeral head articulates with the shallow glenoid fossa of the scapula. The three-to-one humeral-head-to-glenoid-surface ratio allows this joint to enjoy the greatest mobility of any joint in the body. It is especially susceptible to dislocation. Like the AC joint, the GH joint is stabilized by several ligaments and muscles.

The subacromial space is defined superiorly by the coracoacromial arch and inferiorly by the greater tuberosity of the humerus. This space includes the rotator cuff tendon, the long head of the biceps, and the subacromial bursa. The rotator cuff includes the supraspinatus muscle, which helps abduct the arm; the teres minor and the infraspinatus (external rotators); and the subscapularis (internal rotator). The rotator cuff muscle complex serves as a humeral head depressor (lowers the head in the glenoid).

The biceps muscle has a long head and a short head. The long head of the biceps tendon originates at the supraglenoid tubercle, exits the GH joint, and runs distally through the bicipital groove. The short head arises from the coracoid process. The long head and short head form one tendon distally that inserts into the bicipital tubercle of the radius. The biceps tendon provides flexion and supination of the elbow joint, and the long head of the biceps acts as an additional depressor of the humeral head.

History

As with most musculoskeletal injuries, the patient history is crucial. Many shoulder injuries occur in overhead athletic activities, such as baseball or basketball, and are chronic in nature. However, in the ED, patients often present with new traumatic injuries or with acute exacerbations of chronic conditions. Historical factors relating to the sport—such as repetitive motion, conditioning, and requirements for that sport—are important considerations. Knowledge about the position of the arm at the time of injury, the degree of muscle contraction or relaxation, and the direction of momentum of the athlete help determine the type and severity of the injury.³ Also note any history of previous orthopedic procedures on the shoulder as well as any previous injury or dislocation.

Physical Examination

Examination of the shoulder should be performed with both of the shoulders completely exposed. Compare both sides, looking for asymmetry, bony deformities, and chronic muscular changes. It may help to palpate the opposite shoulder to determine the distinctive anatomy. Palpate the bones of the affected shoulder for tenderness, crepitus, and deformity. The rotator cuff muscles should be palpated along the muscle belly, tendon, and at the insertion at the greater tuberosity. Evaluate the AC joint for tenderness and asymmetry. The entire clavicle should also be examined. Note the active and passive ranges of motion of both the normal and affected shoulder.

A detailed neurovascular examination is very important with all shoulder injuries, but especially with a proximal humerus fracture, due to the proximity of the brachial plexus, axillary nerve, and vasculature. The axillary

nerve supplies motor branches to the deltoid and teres minor and sensory fibers to the skin that overlies the lateral aspect of the upper arm. (Note: The “regiment’s band,” or upper lateral cutaneous nerve of the arm, is the more precise term for this sensory portion of the axillary nerve.) The tip of the shoulder is actually innervated by the supraclavicular nerve. Test and document both, especially with a suspected shoulder dislocation.

Diagnostic Testing

An optimal shoulder series includes three views: a true AP (which unlike the standard AP projects the GH joint without bony overlap), transscapular lateral, and axillary lateral.⁴ Scapular views can be obtained if there is suspicion of a scapular fracture.

Which patients with a shoulder injury require radiographs? One prospective study of 206 patients with shoulder pain obtained radiographs on all patients, and 88% of the radiographs were deemed therapeutically uninformative. Low-risk patients were then defined as:⁵

- those with no fall and no swelling;
- those with a fall but no swelling or pain at rest; and
- those with a fall and pain at rest but no swelling and normal range of motion.

Another area of contention is whether pre- and post-reduction radiographs are required in patients with clinically obvious and likely uncomplicated anterior shoulder dislocations. In one prospective study of 97 patients with possible shoulder dislocations, pre-reduction radiographs did not affect the management in any patients and added about 30 minutes to the treatment time.⁶ In a different retrospective study of 175 shoulder dislocations, only one patient had a change in management dictated by the post-reduction film (a persistent dislocation).⁷ However, the studies to date have been small, and many believe that more data are needed before routine x-raying in such patients is discontinued. One argument for a pre-reduction film involves identification of two-part proximal humeral fracture-dislocations. These fracture-dislocations should never be reduced in the ED, since it is possible to dislocate the articular head from the humeral shaft, leading to permanent avascular necrosis.

Clavicle Fracture

Clavicle fractures account for 5% of all fractures and result from a direct blow to clavicle or a fall on an outstretched arm.⁴ The proximal fragment may be displaced upwards by the action of the sternocleidomastoid, and deformity and crepitus may be palpable over the fracture site. Some experts maintain that all patients with pain, deformity, or crepitus require a chest radiograph, as some reports note that routine clavicle films may miss fractures due to overlap of surrounding structures. The literature, however, provides no strong studies that prove the best approach to radiography. While pneumothorax is a rare complication of clavicle fracture, a lung examination and a careful assessment of the x-ray for pneumothoraces are necessary.⁸

Fractures of the middle third of the clavicle account for

approximately 80% of all clavicular fractures and should be treated with shoulder sling immobilization and pain control.⁹ Until the late 1980s, the figure-of-eight clavicle strap was used to immobilize all middle-third clavicle fractures. The more comfortable simple sling has generally replaced this figure-of-eight strap as randomized, controlled clinical trials show equivalent outcomes.¹¹ The patient should be referred to an orthopedist or family physician experienced with these fractures.

Distal clavicle fractures often produce minimal deformity and may be confused with AC joint pathology. Some types of distal clavicle fractures may require operative repair, so early referral to an orthopedist is useful.

Proximal clavicle fractures are the least common and are difficult to diagnose because of bony overlap. Treatment is usually conservative.¹⁰

Open clavicle fractures, posterior sternoclavicular dislocations, and fractures associated with a pneumothorax require urgent orthopedic and surgical consultation.

Glenoid Fractures

The classic mechanism of injury for a glenoid fracture involves falling onto the point of the shoulder with the arm adducted. An anterior shoulder dislocation may also fracture the glenoid (the so-called Bankart's fracture).

Symptoms of a glenoid fracture include pain, decreased range of motion, and occasionally deformity. Glenoid fractures may be associated with other injuries such as rib fractures, pneumothorax, GH or AC shoulder dislocation, and nerve or tendon injury.

All glenoid fractures require urgent orthopedic consultation. In most cases, a CT scan of the shoulder is also necessary for treatment decisions (the timing of which may be deferred to the consultant).

Proximal Humerus Fractures

Athletes may suffer a proximal humerus fracture when a significant amount of force is transmitted to the humerus, such as a fall onto an outstretched, abducted arm.

Symptoms of a proximal humerus fracture include pain, inability to move the arm, pain with passive range of motion, deformity, swelling, and discoloration. Once identified radiographically, further studies are generally not indicated.

The majority of simple, non-displaced proximal humerus fractures can be treated conservatively with ED immobilization and referral. (Some simple, non-displaced fractures can be managed by a primary care physician.) More than 80% of all proximal humerus fractures are non-displaced and can be immobilized in a sling and swathe.⁴ Comminuted or multi-part fractures usually require open reduction and internal fixation.

Complications from a proximal humerus fracture include avascular necrosis of the humeral head, brachial plexus injury, frozen shoulder syndrome (adhesive capsulitis), and non-union.¹²

Acromioclavicular Separation

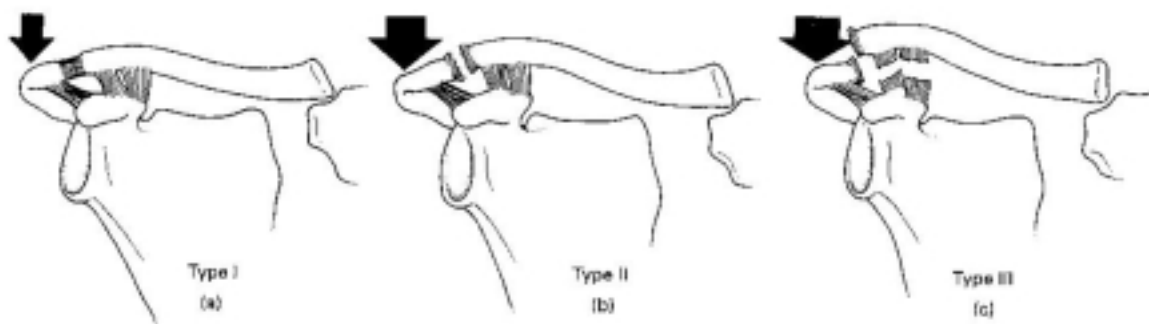
The AC joint is often injured by a fall onto the outstretched hand or onto the point of the shoulder and is one of the most common injuries in bicyclists. Symptoms include point tenderness on or around the joint, pain with movement (especially adduction), swelling, deformity, and discoloration.

While there is a six-stage classification system of AC joint separation, most physicians are familiar with the three-grade system. (See Figure 2.) Severity of injury may range from strains of the ligamentous complex with tenderness over the AC joint and normal radiographs, to joint dislocation and clavicle displacement.⁴

All suspected injuries to the AC joint should be x-rayed to exclude a distal clavicle fracture. Special AC views are best, as standard AP and axillary lateral views of the shoulder rotate the AC joint. Studies indicate that stress radiography views are low yield and therefore are generally unnecessary.¹³

ED management is conservative regardless of grade of injury. Minor injuries can be treated with sling immobiliza-

Figure 2. Acromioclavicular separation types.



- Type I (a): Ligamentous strain—no deformity, but tenderness of AC joint
- Type II (b): Rupture of acromioclavicular ligament—can have slight deformity on physical examination
- Type III (c): Rupture of both acromioclavicular and corioclavicular ligament—significant deformity on physical examination, bottom of clavicle at or above top of acromion on x-ray

Reproduced with permission from: Harries M, Williams C, Stanish WD, et al, eds. *Oxford Textbook of Sports Medicine*. New York: Oxford University Press; 1996:454. Figure 1.

tion, non-steroidal anti-inflammatory drugs (NSAIDs), ice, and relatively early mobilization. Grade III injuries require outpatient orthopedic referral and may benefit from operative intervention in selected cases.

Glenohumeral Dislocations

More than half of all dislocations treated by the emergency physician involve the GH joint. The GH joint may dislocate anteriorly, posteriorly, inferiorly, or superiorly. Anterior dislocations account for more than 95% of all shoulder dislocations.¹⁴ They are exceedingly common in contact sports like football, rugby, lacrosse, and wrestling. Posterior dislocations are rare and usually result from a seizure or electrical injury.¹⁵

When the humeral head dissociates anteriorly from the glenoid fossa, it can rest under the inferior rim of the glenoid, beneath the coracoid process, and, less commonly, in an intrathoracic or subclavicular fashion. (See Figure 3.) The mechanism of injury for anterior dislocation is commonly abduction, extension, and external rotation. (Think of a football quarterback about to pass downfield who gets struck in the arm before he starts the power portion of his throw.)

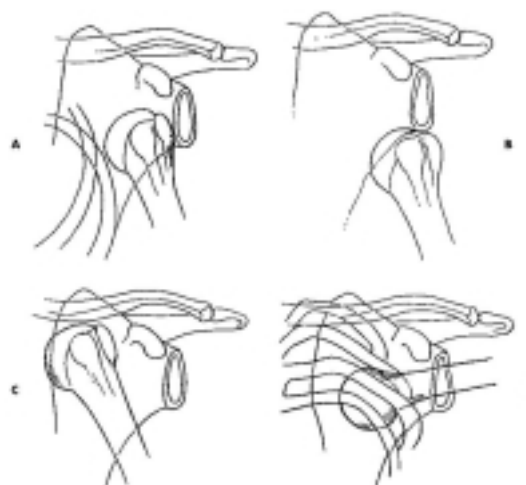
Patients complain of exquisite pain around the shoulder, and the shoulder is often held in external rotation and abduction. There is often a prominent acromion and depression of the area normally occupied by the humeral head, leading to a “squared off” deformity to the arm.

The axillary nerve supplies sensation to the skin that overlies the lateral aspect of the shoulder, and motor innervation to the deltoid and teres minor muscle. Assess and document the status of the axillary nerve before and after reduction, as axillary nerve injury is seen in 5%-54% of patients.¹⁶ Fortunately, nerve function usually returns with time. Athletes who sustain injury to the axillary nerve have variable prognosis for recovery, though return of function is typically good to excellent.¹⁷ Other neurovascular injuries include damage to the brachial plexus, radial nerve, and axillary artery. The most common bony deformity is a Hill-Sach’s lesion. This involves indentation of the humeral head by the inferior glenoid or the coracoid process. Fracture of the greater tuberosity is also possible, and disruption of the rotator cuff can occur with inferior GH shoulder dislocations, especially in those over the age of 40.

Posterior shoulder dislocations comprise only 2% of all GH dislocations and are frequently missed.¹⁸ The injury may occur after a fall onto an outstretched hand with the arm in flexion, adduction, and internal rotation or from a direct blow to the anterior shoulder.⁴ On examination, abduction is severely limited and external rotation is blocked. The shoulder has a flattened, squared-off appearance with a prominent coracoid process. The humeral head may be palpated posteriorly.⁴ *Standard radiographs may appear deceptively normal.* However, there are some signs that can be helpful when present. The “rim sign” refers to the increased distance between the anterior glenoid rim and the articular surface of the humeral head on a true AP view. There may be a loss of the elliptical overlap of the humeral head and the glenoid fossa or a “light-bulb” appearance to the humeral head because the shoulder is internally rotated.⁴

Inferior GH dislocation, also known as luxatio erecta, is rare but striking in its presentation. The classic presentation is an arm that is hyperabducted and locked above the head. Mechanism of injury is hyperabduction of the humerus,

Figure 3. Types of anterior glenohumeral dislocations.



A: subacromial; B: subglenoid; C: subclavicular; D: intrathoracic.

Reproduced with permission from: Marx JA, Hockberger RS, Walls RH, et al. eds. *Rosen's Emergency Medicine*. 5th ed. St. Louis: Mosby; 2002:593. Figure 46-26. With permission from Elsevier Science.

General Treatment Principles For Musculoskeletal Injuries

The RICE regimen (rest, ice, compression, and elevation) is generally recommended for patients with orthopedic sports injuries. Analgesia—usually NSAIDs—may also be appropriate depending on the circumstances.

A systematic literature review suggests that melted ice water applied through a wet towel for 10-minute intervals is most effective in lowering the temperature of the underlying structures, but there is no proof that this affects clinical

outcome.⁹³ The target temperature reduction is 10°C-15°C. Using repeated rather than continuous ice applications helps sustain reduced muscle temperatures without compromising the skin. There are no large, randomized studies to help the physician decide how often and how long to use ice.⁹⁴

Heat is generally not recommended for acute injury, but it has theoretical benefit. No large, controlled trials of heat therapy for acute injury were found in one MEDLINE search.⁹³

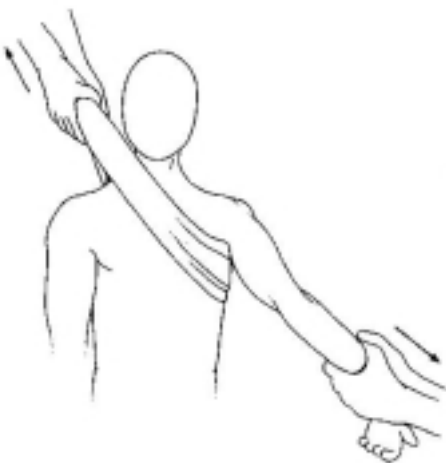which then impinges on the acromion causing a tear in the inferior GH capsule with disruption of the rotator cuff. Rarely, a violent force directly applied to the shoulder from above can produce this injury.¹⁸

Obviously, all dislocations of the GH joint require reduction. There are several common and accepted methods of reducing GH shoulder dislocations. The vast majority of anterior dislocations can be reduced by the emergency physician without orthopedic consultation. Though previous doctrine held that patients generally required conscious sedation prior to reduction attempts, new research indicates that this may not be necessary. Several studies show that intraarticular lidocaine is an acceptable alternative to conscious sedation. Reduction success rates are statistically similar in the conscious sedation and intraarticular lidocaine groups.¹⁹ Intraarticular lidocaine is similarly effective in facilitating reduction and reducing pain but significantly shortens ED stays and reduces costs significantly.^{20,21} The procedure of intraarticular analgesia begins with prepping the shoulder with povidone-iodine. Inject 20 mL of 1% lidocaine via a long 20-gauge needle, from just off the lateral edge of the acromion.²¹ Certain methods of reduction (such as scapular manipulation) require neither conscious sedation nor local anesthetics.

The *traction-counter-traction method* of shoulder reduction involves an assistant who holds a sheet placed around the torso in the axilla and the physician placing traction on the affected limb. This can dislodge the humeral head from its resting position under the glenoid or coracoid. Quite a lot of traction is generally required to overpower the muscles and tendons that are maintaining the dislocated position. (See Figure 4.)

The *Stimson method* involves placing the patient prone with the dislocated limb hanging off of a stretcher. A 10-

Figure 4. The traction-counter-traction reduction.



This is the safest and most effective method of reducing an anterior dislocation. If an assistant is unavailable to apply counter-traction, the sheet around the patient's body can be attached to the stretcher.

Reproduced with permission from: Harries M, Williams C, Stanish WD, et al, eds. *Oxford Textbook of Sports Medicine*. New York: Oxford University Press; 1996:429. Figure 12.

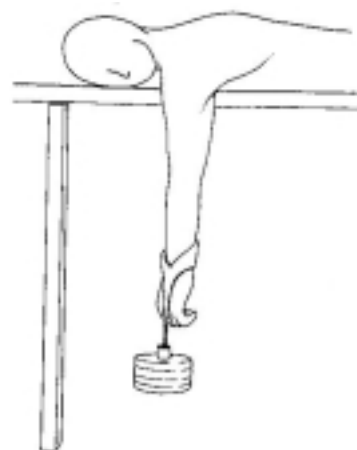
pound weight is attached to the extremity and allowed to hang. As the muscles relax, the shoulder will auto-reduce in about 20 minutes.²² (See Figure 5.)

The *external rotation method* involves gently and slowly externally rotating the shoulder and flexing the shoulder to 90°. This will reposition the humeral head about the glenoid or coracoid and generally effect reduction. An alternative technique involves adducting the shoulder so the patient's elbow is against his or her chest wall, then slowly externally rotating the arm completely. The *Milch technique* is similar to external rotation, but it involves hyperabduction first, then external rotation when the arm is fully hyper-abducted, as if "picking an apple from a tree." One study indicated that the Milch technique was easy to employ and had equal success rates when used by both junior and senior staff. Additionally, they found that 73% of patients who underwent shoulder reduction with this technique did not require any sedation.²³

Scapular manipulation involves having the patient lie prone with affected arm hanging off the bed or having the patient sit up while an assistant applies forward traction to the arm. The physician uses one hand to rotate the inferior tip of the scapula medially while stabilizing the superior and medial edges with the other hand.⁴ (See Figure 6 on page 7.) Unlike the other techniques, scapular manipulation attempts to reposition the glenoid fossa rather than the humeral head. Studies show that the procedure is simple and the reduction is accomplished in less than a minute in most cases. This technique may also reduce the need for premedication. McNamara demonstrated that no premedication was needed in 64% of patients who were reduced with this technique.²⁴

A recently introduced technique for the reduction of anterior shoulder dislocations is the *Spaso technique*.²⁵ To

Figure 5. The Stimson maneuver.



The patient lies prone with a weight attached to the wrist. The technique is easy to perform and comfortable for the patient. However, it is time-consuming.

Reproduced with permission from: Harries M, Williams C, Stanish WD, et al, eds. *Oxford Textbook of Sports Medicine*. New York: Oxford University Press; 1996:429. Figure 11.

perform this reduction, place the patient in the prone position and gently grasp the wrist on the affected side. The limb should gently and slowly be elevated until it is vertical; then, traction should be applied. While maintaining traction, the shoulder should be gently externally rotated. It may be necessary to palpate the humeral head and gently nudge it into the glenoid fossa. A recent article indicated that this technique is highly effective in reducing anterior shoulder dislocations and (in their study) induced no complications.²⁵

Reduction of posterior dislocations involves axial traction with pressure on the humeral head and slow external rotation. Reduction of luxatio erecta is accomplished via traction applied in an upward and outward direction on the extended arm and countertraction applied across the top of the shoulder and chest wall in the opposite direction.¹⁸ Orthopedic consultation may be helpful.

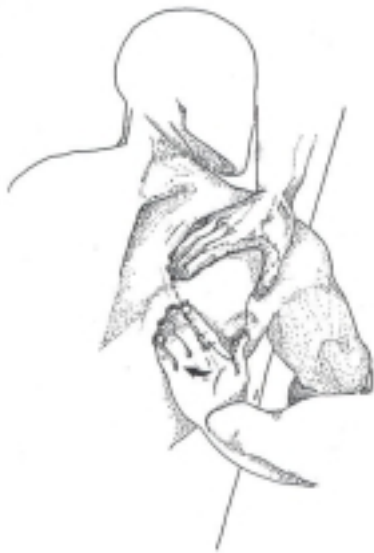It is very important to reassess the shoulder examination following successful reduction, as it is possible to injure the axillary nerve or fracture the humerus, glenoid, or other bony structure.

Teens and young adults who dislocate their shoulder have a recurrence rate of 79%-100% and must receive orthopedic follow-up.²² Patients should also receive appropriate analgesia and sling immobilization for two or three weeks.²⁶ The duration of sling immobilization varies but concerns over frozen shoulder have reduced the length in recent years. In most cases, two weeks followed by a rehabilitation program is suggested.

Rotator Cuff Injuries

The rotator cuff muscles play an important role in virtually every sport but are absolutely crucial to the overhead

Figure 6. Scapular manipulation.



Proper hand positioning and direction of rotation during shoulder relocation using the scapular manipulation technique.

Reproduced with permission from: Marx JA, Hockberger RS, Walls RH, et al. eds. *Rosen's Emergency Medicine*. 5th ed. St. Louis: Mosby; 2002:595. Figure 46-31. With permission from Elsevier Science.

athlete. Participants in tennis, basketball, volleyball, and baseball frequently experience rotator cuff injuries.

Acute injury of the rotator cuff is marked by a sudden tearing sensation in the shoulder followed by severe pain radiating to the arm. The pain is often poorly localized but may be present at the insertion of the rotator cuff tendon, along the mid-substances of the rotator cuff muscles, or may radiate up to the neck or down to the arm. Subjective weakness of the shoulder muscles as well as history of recurrent dislocations may be present. An acute tear of the rotator cuff is uncommon. Neer proposed that 95% of rotator cuff tears are related to chronic impingement of the rotator cuff between the humeral head and the coracoacromial arch.⁹⁷ It can result from falling on an outstretched arm. Typically, tears are chronic and result from progressive degeneration.²⁷

Litaker et al identified three components of the physical examination that can identify rotator cuff tears. These include supra- and infraspinatus atrophy, weakness with elevation or external rotation of the shoulder, and the impingement sign.²⁸ Impingement refers to inflammatory changes due to repetitive compression of the rotator cuff and associated structures between the humeral head and coracoacromial arch.²⁷ The Neer's impingement test involves moving the patient's straightened arm to full abduction. The Hawkins' impingement test involves positioning the patient's arm in 90° of abduction and 90° of elbow flexion, then rotating the arm inwardly across the patient's body. Pain reproduced by either one of these maneuvers is considered an impingement sign.²⁷

Radiographs may exclude bony problems such as thick acromion, bone spur, glenoid erosions, Hill-Sach's lesions, and others. While the radiographs may show evidence of degeneration, the hallmark of a complete tear of the rotator cuff complex is superior displacement of the humeral head that is best seen in the externally rotated AP view.⁴ Other imaging techniques such as magnetic resonance imaging (MRI) or arthrogram should be reserved for outpatient evaluation.

Acute tears should be immobilized in a sling and referred for prompt orthopedic evaluation. Unless otherwise indicated, most patients should be started on NSAID therapy. Many require narcotic analgesia. Rest, avoidance of painful activities and positions, and orthopedic referral are important. It is usually not possible or necessary to differentiate between an acute tear, a chronic tear, or a flare of rotator cuff tendinitis in the ED. These patients should be treated in the same manner and given timely referral.

Biceps Tendinitis

In pitchers, weight-lifters, and other athletes, the long biceps tendon may become inflamed. Symptoms of biceps tendinitis include pain with shoulder extension or elbow flexion, pain when trying to reach into the back pocket, and pain around the anterior shoulder. On physical examination, palpation of the tendon within the bicipital groove reproduces the pain, as does forearm supination.

Treatment of biceps tendinitis is similar to other overuse syndromes. Most patients should be begun on

oral NSAID therapy. Athletes should be encouraged to rest, ice, and avoid painful movements and positions. Orthopedic referral is appropriate in most patients if symptoms persist.^{29,30}

Emergency Department Evaluation: Hand Injuries

History And Physical Examination

The patient history should include the position of the hand at the time of injury, mechanism of injury, previous hand injuries, occupation, and hand-dominance. Physical examination should assess for tenderness, tendon integrity, joint stability, range of motion, two-point sensation, capillary refill, and motor function.³¹

Mallet Finger

Mallet finger (also known as baseball finger) is a rupture of the extensor tendon that attaches to the dorsal side of the distal phalanx of the finger. This tendinous injury occurs when there is a forced flexion of a fully extended finger, commonly involving a baseball or volleyball striking the tip. This forced flexion can cause a rupture of the extensor tendon or an avulsion of the bone at the tendon insertion. With the extensor mechanism disrupted, the patient will be unable to fully extend the distal phalanx, although passive extension will be possible.

While the physical examination will be diagnostic, a radiograph should be obtained to rule out an associated avulsion fracture of the distal phalanx. Treatment is conservative and involves immobilizing the joint in an extension splint in a neutral position (some recommend slight hyperextension) for 6-8 weeks. The patient should be referred to a hand specialist for follow-up.

Jersey Finger

Jersey finger, or a tear of the flexor digitorum profundus, is essentially the opposite of mallet finger, as there is a forced extension of the finger during an effort to actively flex the digit. The classic description is that of a football player trying to grab his opponent's jersey as the opponent is running downfield. The physical examination, again, is diagnostic, as the patient is unable to flex the distal phalanx at the distal interphalangeal joint. Radiographs should be obtained to rule out an associated avulsion fracture of the distal phalanx.

Jersey finger is usually managed operatively within 14 days of the injury. The finger should be splinted with the finger and wrist flexed and urgently referred to a hand specialist.

Gamekeeper's Thumb

Gamekeeper's thumb, also known as skier's thumb (since skiing is now more common than twisting off the heads of rabbits), refers to injury of the ulnar collateral ligament (UCL) of the thumb's metacarpal phalangeal joint. On examination, there is tenderness over the ulnar side of the joint and weakness of pinch. Valgus stress testing of the thumb UCL should be done both in full extension and in 30°

of flexion. Greater than 35° of joint laxity or 15° more laxity than the contralateral side UCL indicates a complete UCL rupture.^{4,32}

Radiographs should be obtained before stressing the joint to exclude associated avulsion or condylar fractures. Treatment of a partial UCL rupture involves immobilization in a thumb spica cast for four weeks. Complete tears require surgery. All patients suspected of this injury should be immobilized and referred to an orthopedist, as under-diagnosis can lead to chronic disability.⁴

Emergency Department Evaluation: Selected Neurologic Injuries

While a full discussion of neurologic sports injuries is beyond the scope of this article, the January 2000 issue of *Emergency Medicine Practice*, "Mild Head Trauma: Appropriate Diagnosis And Management," provides an excellent overview. For a complete discussion of cervical spine injuries, see the October 2001 issue of *Emergency Medicine Practice*, "Cervical Spine Injury: A State-Of-The-Art Approach To Assessment And Management."

Brachial Plexus Injuries

Brachial plexus injuries are common in contact sports, especially football and rugby. A "stinger" or "burner" is classically defined as unilateral burning dysesthesias from the shoulder to the hand, with occasional weakness or numbness in the C5 and C6 distribution.³³ The mechanism of injury is usually sudden forced flexion forward or laterally of the cervical spine, resulting in a stretch injury, presumably to the sixth cervical spinal nerve root.

For the vast majority of brachial plexus injuries, the consequences of cervical root strains are minimal. Patients experience pain, numbness, and tingling of the extremity opposite to the direction of lateral bending (i.e., if the head is forced to the left side, the right arm will be affected). Rarely, there can be more severe damage to the nerves. The symptoms typically last minutes but can persist for days to weeks. *The unilaterality, brevity, and pain-free range of motion in the athlete can assist in discriminating between a "stinger" and a cervical cord injury.*³³ Neck pain is usually not a prominent feature in traction injuries.³⁴

ED examination of brachial plexus injuries should include a thorough neurological examination. Compare the strength and sensation to the non-affected side. Additionally, examine the cervical spine and image when indicated. (See the October 2001 issue of *Emergency Medicine Practice*.) MRI is reserved for patients in whom a cervical spinal cord injury cannot be excluded or as an outpatient test for those with persistent symptoms.³⁴

Rest and NSAID therapy may be helpful. Patients should have a thorough and normal neurological examination before resuming athletic activities. Some may benefit from a short course of physical therapy.^{34,35}

Transient Quadriplegia

Transient quadriplegia most frequently occurs with an axial load injury to the cervical spine, or after hyperextension

or hyperflexion.³⁶ Typically, the patient experiences transient upper- and lower-extremity paralysis and numbness, which resolves over a period of minutes. Plain radiographs and computed tomography of the spine, as well as MRI of the spine, are usually normal (but still may be indicated depending on the clinical circumstances, such as cervical spine tenderness, etc.). Before the athlete is allowed to return to play, spinal stenosis must be ruled out, since this is an absolute contraindication for return to training.³⁶ Cervical spinal stenosis can increase the risk of permanent neurologic injury.^{37,38}

Emergency Department Evaluation: Elbow Injuries

Elbow Dislocation

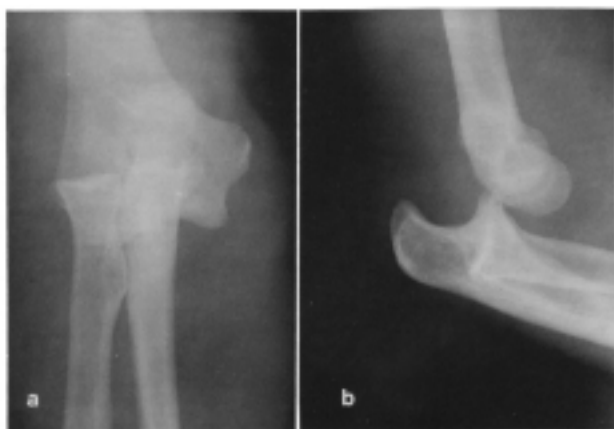The elbow is second only to the shoulder as the major joint most frequently dislocated. Football players and other contact sports participants are particularly vulnerable. Most dislocations are posterior, although the elbow may also dislocate medially, laterally, or anteriorly.^{4,39} (See Figure 7.)

The classic mechanism of injury is a fall onto the outstretched hand with the elbow extended. Patients will have a marked deformity on the injured side and a prominent olecranon. They often maintain the elbow in about 45° of flexion.

Frequent neurovascular examinations are crucial. The median nerve and brachial artery are at particular risk. Brachial artery injury is noted in 5%-13% cases.⁴⁰ Nerve and vascular injury after reduction have been reported.^{40,41}

Treatment is prompt reduction. If the neurovascular status of the extremity is compromised, immediately reduce the elbow. Reduction of a posterior dislocation is accomplished by stabilization of the humerus and gentle traction of the wrist with flexion of the elbow if the joint does not easily reduce. In most cases, elbow reduction is uneventful. Most patients will require conscious sedation or intra-

Figure 7. Complete posterior dislocation of the elbow.



AP and lateral views of posterior elbow dislocation.

Reproduced with permission from: Harris JH Jr, Harris WH, Novelline RA. *The Radiology of Emergency Medicine*. 3rd ed. Baltimore: Williams & Wilkins; 1993:344. Figure 5.13.

articular anesthesia. Obtain post-reduction films and range the elbow through flexion and extension to ensure stability. Immobilize the elbow in 90° of flexion. Phone consultation with an orthopedist may be helpful, since the stability of reduction and neurovascular status of the elbow must be closely monitored, especially for development of a forearm compartment syndrome. Most patients who dislocate their elbow without comorbid fractures have an excellent long-term prognosis.

Emergency Department Evaluation: Hip Injuries

Anatomy

The hip is a ball-and-socket joint that consists of the acetabulum and the proximal femur 2-3 inches below the lesser trochanter. There is a strong fibrous capsule surrounding the joint.

Overview

Acute hip pain in athletes is almost always the result of a strain or musculotendinous injury. In children and adolescents, these injuries are often avulsion fractures involving the iliac crest, anterior superior and inferior iliac spines, and lesser trochanter or ischial tuberosity. Hip fractures and dislocations are uncommon in sports activities and usually occur as a result of a high-speed collision.³²

Avulsion fractures, such as avulsion of the anterior superior iliac spine, are the result of sudden, forceful contraction of the sartorius muscle. This fracture is usually seen in children and adolescents before the physis closes. The same mechanism in adults results in a strain instead of a fracture.

History And Physical Examination

As with any injury, the surrounding events should be noted. Determine the position the leg was in when the injury occurred, whether there was a pop heard or felt, and whether the patient could ambulate or resume play immediately after the injury. True hip joint pain often localizes to the groin. Examine the involved leg for deformity, shortening, rotation, and ecchymoses. Active and passive range of motion should be evaluated as long as the physician is reasonably sure there is no fracture or dislocation present. Look for tenderness of the iliac crest, pubic rami, or ischial rami. Hip pain with weight-bearing despite negative radiographs may indicate an occult fracture of the joint.

Musculotendinous injuries around the hip are usually the result of an actively contracting muscle that encounters abrupt resistance. This is most commonly seen in track and field but can occur in any sport that involves rapid acceleration and deceleration, such as soccer or missing a kick in football.

Symptoms include a pop or snap and sudden, severe localized pain and immediate disability. Walking is difficult or impossible. The site of the injury is tender, and swelling is variable. The muscle is usually tense. Suspect an avulsion fracture if there is tenderness on palpation at any of the tendon insertions.

Muscular injury is frequently encountered in the three major muscle groups of the leg: the hamstrings, quadriceps, and the iliopsoas. Strain of the hamstrings is common with running and sudden acceleration. The patient develops sudden and severe pain in the posterior thigh. Range of motion of the hip is painful, and no bony tenderness is present. Treatment involves crutches with toe-touch weight-bearing (only the toes bear weight) as tolerated.

The quadriceps are the most common muscular groups to suffer complete tears. When the muscles are contracted suddenly against the body's weight, such as stumbling to prevent a fall, the quadriceps can suffer various degrees of tearing. On examination, there is pain with passive and active knee extension; with a complete tear, active knee extension against gravity is impossible. Treatment is limited to weight-bearing with crutches.

Injury of the iliopsoas is commonly seen in gymnasts and dancers and is the result of sudden, forceful hip flexion against resistance. There is sudden, severe pain in the groin, thigh, or low back. There may also be abdominal pain at the origin of the iliopsoas. On examination, the groin is tender to palpation and there is pain with active hip range of motion. Radiographs of the femur should be obtained to exclude a fracture of the lesser trochanter. Treatment is bedrest for 7-10 days with partial flexion at the knee and hip.⁴

With most muscular injuries, complete the evaluation with a pelvic or hip film to exclude associated avulsion fractures. The standard treatment of compression and ice is difficult to accomplish in the hip. Ambulation with crutches and bedrest are recommended.⁴² As with other musculotendinous injuries, active and isometric stretching should be started in 48 hours.

A contusion of the iliac crest is also known as a *hip pointer*. The iliac crest is very vulnerable to direct blows due to its poor protection. This injury may result in severe disability because the iliac crest serves as an anchor for abdominal and hip musculature. The history is significant for a direct blow to the hip, such as from a football helmet or fall onto a hard surface (which is common in soccer, football, and ice hockey). This painful blow is instantly disabling. On examination, the iliac crest is tender and there is a variable amount of swelling. The abdomen is often rigid due to abdominal wall spasm.

Radiographic evaluation of the pelvis may reveal a compression fracture. Consider intraabdominal injury in the presence of significant abdominal tenderness. In addition to ice and analgesics, a six- to eight-day steroid burst may reduce the duration of disability.⁴²

Emergency Department Evaluation: Thigh Injuries

Quadriceps Tendon Rupture

Quadriceps (or extensor tendon) rupture results from powerful muscle contractions secondary to a fall or in conjunction with severe ligamentous disruption at the knee. This is typically an injury seen in older patients, but it may occur in younger patients involved in jumping activities.⁴³ In

athletes, the rupture most often occurs in high-power sports events, such as the high jump, basketball, and weight-lifting.⁴⁴ Patients report hearing a loud pop and are immediately unable to extend the leg or bear weight. They may complain of buckling of the knees or inability to walk up stairs or up an incline.⁴⁵ Often there is a palpable soft-tissue defect proximal to the superior pole of the patella, but this may be obscured by edema.⁴³ All patients have marked weakness of the knee extensors, and most have an inability to perform a straight leg raise test when supine. Radiographs of the knee may reveal a poorly defined suprapatellar mass, an obliterated quadriceps tendon, and a joint effusion.⁴⁵ Early diagnosis is important, as surgical repair within 48-72 hours is necessary to preserve the extensor mechanism of the knee.⁴³

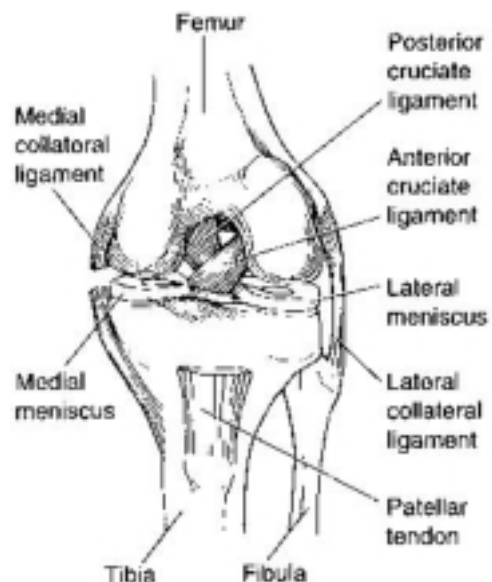
Emergency Department Evaluation: Knee Injuries

There are 1.3 million visits to U.S. EDs because of knee trauma each year.^{46,47} Knee injuries produced by recreational sports tend to follow a different pattern than other mechanisms of casual injuries. In one study of 208 males who underwent knee arthroscopy after trauma, a significantly greater number of anterior cruciate ligament (ACL) tears were associated with sports activity ($P = 0.032$). Sports injuries also resulted in a significantly greater number of meniscal injuries ($P = 0.028$), while sedentary patients had a greater prevalence of osteochondral fractures (10%) than the sports group (5%).⁴⁸

Anatomy

The knee (see Figure 8) is a complex diarthrodial hinged joint that is frequently injured during sports activities. The knee is positioned between the two longest bones in the

Figure 8. Knee anatomy.



Reproduced with permission from: Anderson MK, Hall SJ. *Sports Injury Management*. Baltimore: Williams & Wilkins; 1995:271. Figure 81C.

body—the femur and the tibia—but has minimal bony stability. There are three primary articulations within the joint complex. The patellofemoral articulation involves the patella and the distal femur, while the other two articulations involve the distal femur and the proximal tibia. The non-bony elements include two menisci, four ligaments (medial and lateral collateral ligaments and the anterior and posterior cruciate ligaments) and the surrounding capsule. The fibrocartilaginous menisci distribute weight and stabilize the knee. The medial meniscus is injured more frequently than the lateral meniscus.⁴⁰

The medial and lateral collateral ligaments resist valgus and varus stress, respectively. The anterior and posterior cruciate ligaments resist anterior and posterior stress and are the major stabilizing ligaments of the knee. The ACL is ruptured more often.

History

A careful history is often needed to ascertain the acuteness of the injury, as chronic overuse injuries can present with acute exacerbations. (See **Table 2** and **Table 3**.) An audible pop at the time of the injury and immediate swelling suggest a significant internal derangement. *Sudden onset of a large effusion suggests an ACL injury.* Note the patient's ability to ambulate immediately following the injury and the position of the leg at the time of injury. For example, a

Table 2. Differential Diagnosis Of Acute Traumatic Knee Pain.

Most serious

- Knee dislocation
- Fracture of distal femur, patella, proximal tibia, or fibula
- Patellar or quadriceps tendon rupture
- Meniscal injuries
- Ligamentous injuries

Most common

- Sprains/strains
- Contusions
- Patellar dislocation or subluxation

Table 3. Significant Historical Points In Knee Injuries.

- Acute onset of pain within 72 hours of injury
- Audible pop and immediate swelling with twisting or forced hyperextension
- Direct blow to anterior tibia, forced hyperextension, or axial load
- Direct blow to the medial or lateral aspect of the knee
- Varus or valgus stress to knee
- Twisting injury—painful popping and catching, delayed swelling
- Direct blow to patella or hyperflexion
- Prior knee surgery

Source: Beatty JH, ed. *Orthopaedic Knowledge Update 6: Home Study Syllabus*. Rosemont, IL: American Academy of Orthopaedic Surgeons; 1999.

football player tackled from the side while his foot is planted is at risk for a medial collateral ligament injury. It is especially important to consider the hip as a source of referred knee pain.

Determine any previous knee injuries, any knee surgery, and the functional status before injury.

Physical Examination

The examination begins with an inspection of the entire limb for deformity, bruising, and swelling. (See also **Table 4**.) Comparison to the opposite leg is helpful. Palpate for localized tenderness, beginning in the non-painful areas. The knee's active and passive range of motion, within the limits of pain, should be tested next. It is important to specifically test the knee extension against gravity to ensure integrity of the extensor mechanism (quadriceps, patella, and patellar tendon). Specific tests are then performed to evaluate the mechanical integrity of the components of the knee joint. Obtain radiographs before stressing the knee if a fracture is likely.

Ligamentous injuries of the knee usually occur as a result of hyperextension or abnormal rotation. Identifying an internal derangement is more important than identifying the specific injury.

A recent literature review compared physical examination to either MRI or arthroscopy for meniscal or ligamentous injuries of the knee. While there were limitations in the data, the authors found the Lachman test excellent for both ruling in and ruling out a tear of the ACL. The anterior drawer test was not particularly useful under any conditions, and there is no reliable examination for meniscal injuries. Potentially useful physical findings include alignment during standing or walking, active and passive range of motion, the presence of effusion, joint line tenderness, and the Lachman test.⁴⁹

Physical Examination Maneuvers

The value of any of these maneuvers is best determined by comparison to the uninjured knee, as abnormalities may be subtle.

The *collateral ligament stress test* tests the integrity of the

Table 4. Significant Physical Examination Findings In Knee Injuries.

- Effusion or acute swelling
- Positive Lachman test
- Patellar tenderness or abnormal position
- Tenderness of the lateral or medial aspect of the knee or head of fibula
- Joint line tenderness or positive McMurray's test
- Inability to straighten or flex the knee greater than 90°
- Inability to perform straight-leg raise
- Positive posterior drawer test
- Valgus or varus joint instability
- Inability to bear weight for four steps without assistance

Adapted from: Beatty JH, ed. *Orthopaedic Knowledge Update 6: Home Study Syllabus*. Rosemont, IL: American Academy of Orthopaedic Surgeons; 1999.

medial and lateral collateral ligaments. Injuries to the medial collateral ligament are based on the amount of laxity present. The knee should be tested by applying a valgus stress in full extension and 30° of knee flexion. A grade I injury has 0-5 mm of laxity, a grade II injury has 5-10 mm of laxity, and a grade III injury, which means complete ligamentous disruption, has greater than 10 mm of laxity. When the knee is tested in full extension, any laxity with valgus stress implies complete medial collateral ligament disruption.⁵⁰ Injury to the lateral collateral ligament, which is uncommon, is tested by applying a varus force to the knee in extension and 30° of flexion. Lateral laxity of more than 10 mm without a firm endpoint reflects complete lateral collateral ligament rupture, while less than 10 mm of laxity suggests a partial tear.⁵¹ Whenever testing laxity, compare to the uninjured knee, as some patients have considerable normal laxity.

The **Lachman test** evaluates the ACL and is the single best clinical test for determining the integrity of the ACL. It is also one of the only reliable tests in a patient with an acute hemarthrosis.^{4,52} Have the patient lie supine and flex the knee to 20°-30°. The examiner stabilizes the femur with one hand and pulls the tibia forward with the other hand, while estimating the amount of anterior movement. A distinct endpoint at which forward displacement stops suggests that the ACL is intact. The anterior drawer test is much less reliable than the Lachman test for evaluating the ACL (70% vs. 99% accuracy in one study) and should not be used.^{40,53} (See Figure 9.)

The **posterior drawer test** is the gold standard used to evaluate the posterior cruciate ligament. The examiner flexes the patient's knee to 90°, anchors the thigh, and pushes the tibia backward. The location of the anterior proximal tibia in relation to the patella and femoral condyles is used to estimate the posterior movement of the tibia on the femur. A positive test results when the tibia moves posterior to the femoral condyles.⁴⁰ A blinded, randomized, controlled study of 39 patients showed it to be 96% accurate, 90% sensitive, and 99% specific. (The examiners in this study, however, were orthopedic surgeons trained in sports medicine.⁵⁴)

The **McMurray test** evaluates the menisci. The examiner grasps the lower leg and flexes and extends the knee while internally and externally rotating the tibia on the femur. The other hand is used to palpate the knee for a clicking

sensation, which constitutes a positive test. It is also considered significant if the patient experiences pain during internal and external rotation.⁵⁵ This test is not specific for meniscal problems as it also detects soft-tissue injuries.⁴

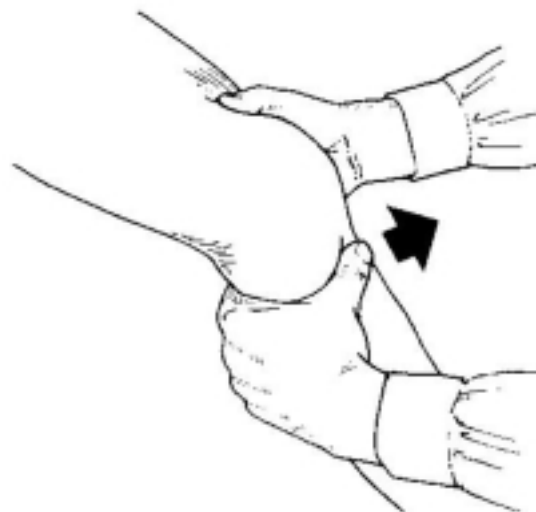
The **apprehension sign** is used to diagnose a partial dislocation (subluxation) of the patella or recent patellar dislocation that has spontaneously reduced. This sign describes the anxiety exhibited by the patient as the examiner attempts to slide the patella laterally, which results in pain and forceful contraction of the quadriceps femoris muscle.

Knee Radiography

More than \$1 billion is spent on emergency radiography of the knee each year in the United States, with 90%-92% of these studies showing no fracture.^{46,47} A standard knee series includes the AP, lateral, and, in most hospitals, oblique views. These films should be examined for loose bodies, osteochondral injuries, and avulsion fractures. Additional views, such as a "sunrise" view or "tunnel" view, are sometimes needed. A sunrise view is a tangential view that provides good visualization of the patella and

Continued on page 14

Figure 9. The performance of the Lachman test.

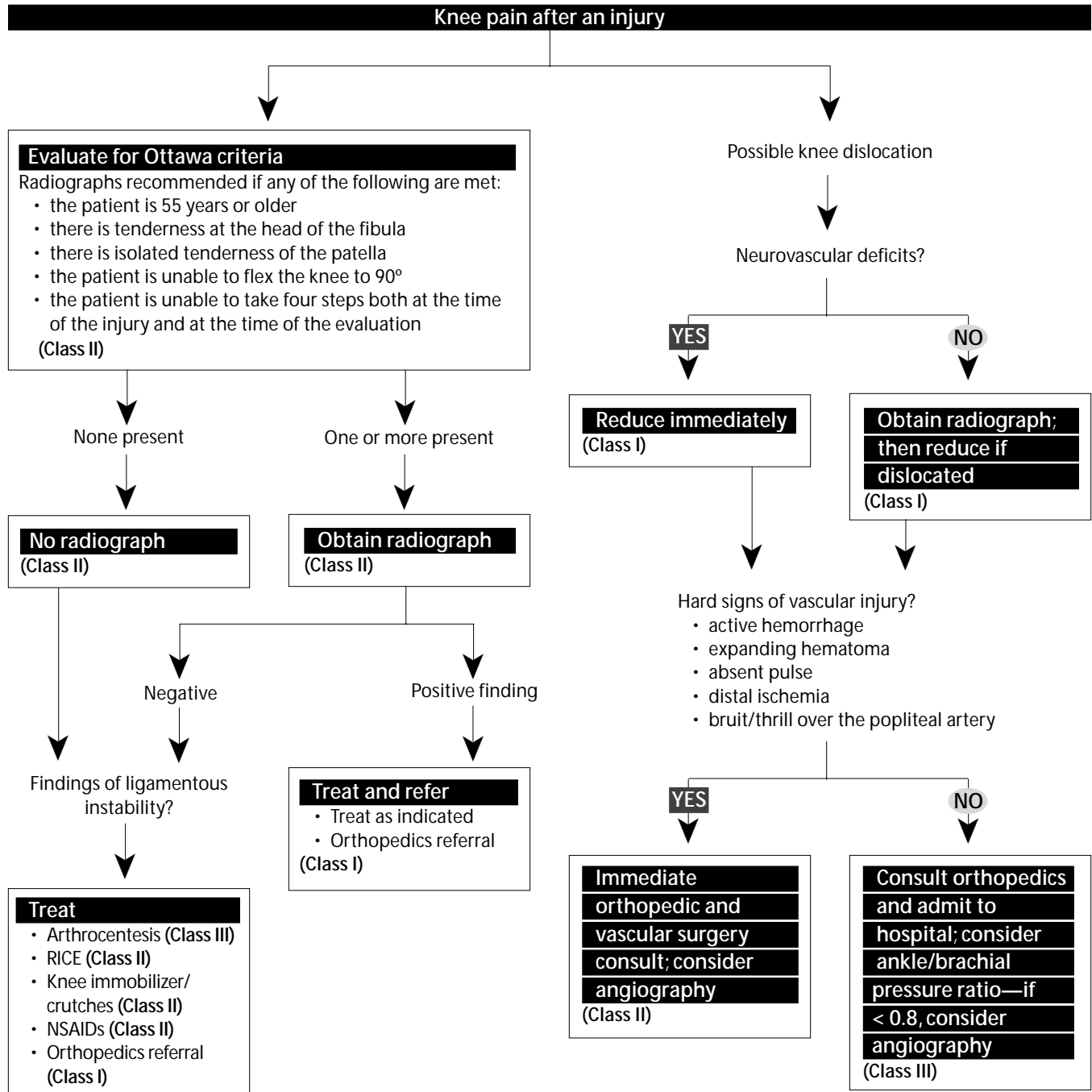


Reproduced with permission from: Simon R. Koenigsnecht S. *Emergency Orthopedics: The Extremities*. New York: McGraw-Hill; 1995:371. Figure 27-9.

Cost-Effective Strategies For Orthopedic Sports Injuries

1. Don't x-ray every knee, ankle, or foot. The Ottawa knee, ankle, and foot criteria are sensitive and specific. Adherence to these criteria whenever possible will decrease the number of knee radiographs ordered.⁵¹
2. Do not order an MRI from the ED for knee injuries. MRI is an outpatient study that should be ordered by the orthopedic consultant who will be managing the patient.
3. Avoid the use of ketorolac for acute musculoskeletal injuries. Ibuprofen has been shown to be just as effective for acute pain and is significantly less expensive. If ibuprofen is ineffective in relieving the patient's pain, opioid narcotic analgesics should be prescribed.
4. Learn to use intra-articular lidocaine to reduce shoulder dislocations. It is cheaper and faster than intravenous sedation and is just as efficacious.^{19,20} ▲

Clinical Pathway: Evaluation Of Knee Injuries



The **evidence for recommendations** is graded using the following scale. For complete definitions, see back page. **Class I:** Definitely recommended. Definitive, excellent evidence provides support. **Class II:** Acceptable and useful. Good evidence provides support. **Class III:** May be acceptable, possibly useful. Fair-to-good evidence provides support. **Indeterminate:** Continuing area of research.

This clinical pathway is intended to supplement, rather than substitute for, professional judgment and may be changed depending upon a patient's individual needs. Failure to comply with this pathway does not represent a breach of the standard of care.

Copyright ©2003 EB Practice, LLC. 1-800-249-5770. No part of this publication may be reproduced in any format without written consent of EB Practice, LLC.

Continued from page 12

patellofemoral joint. A tunnel view images the intercondylar notch and detects tibial spine fractures and loose bodies within the notch.⁴

Clinical decision rules such as the Ottawa or Pittsburgh knee rules are a cost-effective way to improve radiograph utilization. The Ottawa rules were developed from a prospective evaluation of 23 clinical indicators in 1047 adult patients with knee injuries.⁵⁶ The Ottawa knee rules, which have been validated by numerous other investigators,^{57,58} recommend radiographs if any of the following conditions are met:⁵⁹

- the patient is 55 years or older;
- there is tenderness at the head of the fibula;
- there is isolated tenderness of the patella;
- the patient is unable to flex the knee to 90°; or
- the patient is unable to take four steps both at the time of the injury and at the time of the evaluation.

A study of 1522 adults designed to validate the Ottawa knee rules found the sensitivity for detecting clinically important fractures to be 100%.⁵⁷ Like all decision rules, the Ottawa knee rule has its limitations. The rule was not designed to apply to patients younger than 18 years, pregnant patients, patients with isolated skin injuries, patients with injuries more than seven days old, patients with altered level of consciousness, or patients who have multiple injuries.⁶⁰ The Ottawa definition for ambulation is also quite liberal, with any minimal foot transfer, including severe limping, considered as "able to bear weight."⁶⁰

While the Ottawa knee rules were not originally intended for the pediatric population, a recent study evaluated its applicability in children. In a prospective study of 234 patients 2-18 years old, the rule reduced the need for radiography but only had a sensitivity of 92% for detecting fractures.⁶¹

Another clinical decision rule, developed at the University of Pittsburgh, uses different criteria. The Pittsburgh rules were designed using a retrospective review of 11 clinical indicators in 201 patients with knee injuries. The Pittsburgh knee rules recommend radiography in the following circumstances:⁶⁰

- a fall or blunt trauma in patients older than 50 or younger than 12
- a fall or blunt trauma with the inability to walk four steps in the ED

A prospective study of 934 patients found that the Pittsburgh knee rules outperformed the Ottawa knee rules. In the 745 patients in whom the Pittsburgh rules were applied, the sensitivity was 99% and the specificity was 60%. The Ottawa rules were applied in 750 patients and demonstrated a sensitivity of 97% with a specificity of only 27%.⁶⁰

Magnetic Resonance Imaging

MRI is the imaging modality of choice to diagnose signifi-

cant acute and chronic soft-tissue injuries of the knee.

However, at the present time MRI is costly and has limited availability. Since the definitive evaluation of these injuries is rarely necessary on an emergent basis, the use of MRI is best deferred to the consultant.

Anterior Cruciate Ligament Injuries

The ACL is the most frequently injured major ligament in the knee and is frequently torn in skiing and contact sports, most commonly football.⁴ The ACL is injured during recovery from falling backwards (in expert skiers) or hyperflexion and internal rotation of the knee (in lower-level skiers).⁶² This injury can also occur in basketball players when the hyperextended knee is twisted or when the patient collides with another player. An audible pop, immediate swelling, and inability to continue the activity mark this injury. The Lachman test is diagnostic.⁴⁰

Collateral Ligament Injuries

The *medial collateral ligament* is a medial stabilizer of the knee and is most commonly injured by a blow to the lateral aspect of the knee or by the patient planting the foot and then colliding with another athlete.⁴⁰ Patients usually report hearing a pop at the time of the injury, although this finding is not specific. There is often an associated ACL injury as well. A first- or second-degree sprain will have tenderness, usually at the medial femoral epicondyle. Swelling will occur quickly, but bruising is often delayed 24-36 hours. A third-degree sprain may not cause severe pain, but the patient can't continue the activity after the injury, limps, and cannot fully extend the leg.⁴⁰ The degree of injury can be estimated by the amount of joint line opening. An isolated tear usually heals without surgical intervention.

Injury of the *lateral collateral ligament* is less common but more disabling. It occurs via hyperextension with varus stress or from a direct blow or rotation.

Posterior Cruciate Ligament Injuries

Injury to this ligament is less common than to the ACL due to the strength of the ligament. It is usually caused by a direct blow to the anterior tibia or a fall. The posterior drawer test is diagnostic, and treatment is conservative.

Meniscal Injuries

The menisci are often co-injured with other structures, usually as a result of a twisting motion to a flexed knee. Unlike collateral ligament injuries, pain with meniscal injury is usually worse with weight-bearing.⁵¹ The classic clinical triad is joint line pain, swelling, and locking. On examination, there is tenderness and effusion along the medial or lateral joint lines and pain in the posterior aspect of the knee on passive extension and flexion. There may be locking immediately after the injury due to a displaced meniscal fragment.⁴ A positive McMurray test is helpful in the diagnosis, but a negative test does not exclude injury. Evaluate for a locked knee, where the knee becomes fixed in flexion due to a mechanical block from the displaced cartilage.⁶³

Disposition Of Ligamentous And Meniscal Injuries

The definitive treatment of ligamentous and meniscal injuries is not emergent. Patients are to be immobilized, instructed to elevate the leg, and referred to an orthopedist in 2-4 days. The exception is the acutely locked knee, in which case the orthopedist should be consulted while the patient is in the ED.

Knee Dislocation

Despite its dense protective shell of 11 cruciate and collateral ligaments and tendons, significant blunt forces can cause subluxation of the tibia over the femur, causing dislocation of the knee.⁶⁴ This often occurs as a result of a high-speed motor vehicle accident, but it can also occur during a sports activity, such as football, waterskiing, or skateboarding. Knee dislocations are classified according to the direction that the tibia is displaced in relation to the femur. Of knee dislocations, 50%-60% are anterior, but popliteal artery injury is most commonly associated with posterior dislocations.^{65,66} The incidence of popliteal artery injury in association with knee dislocations varies from 21% to 80%.⁶⁷ The risk of vascular injury appears to be less when the dislocation is relatively low-energy, such as those associated with athletic events.⁴

There is a high incidence of spontaneous reduction of a dislocated knee prior to ED evaluation, and the evaluating physician must maintain a high index of suspicion for this injury. The patient may give a history of the knee popping out and then popping back into place. On examination, the knee is usually grossly swollen, painful, and unstable. Sometimes with complete disruption of the joint capsule, the hematoma leaks into the thigh or calf and the knee is almost normal in size. The vascular examination may be normal or show signs of popliteal artery or peroneal nerve injury. Peroneal nerve injury is the most common major neurological problem associated with knee dislocation. The peroneal nerve is evaluated by testing sensation in the first dorsal web space and having the patient extend the big toe or dorsiflex the ankle.⁴

The association between knee dislocations and popliteal artery injury has been known for almost a century.⁶⁸ Despite this knowledge, controversy remains concerning the necessity of angiography of the popliteal artery to determine the presence of a vascular injury.

Historically, all patients with knee dislocations have undergone angiography, even those with a normal vascular examination.⁶⁹⁻⁷² The current recommendation is that patients with low-energy knee dislocations and a normal vascular examination do not require arteriography but do require serial examinations.^{27,51} A study by Miranda et al describes their experience using selective arteriography in 35 patients with knee dislocations over a 10-year period. In this study, patients with hard signs of vascular injury at the time of evaluation had angiography. "Hard signs" included active hemorrhage, expanding hematoma, absent pulse, distal ischemia, or bruit/thrill over the popliteal artery. None of the 27 patients with a negative physical examination during their hospitalization ever developed limb

ischemia, needed surgery for a vascular injury, or experienced limb loss. This limited series demonstrates that serial physical examinations have a 94.3% positive predictive value and 100% negative predictive value in diagnosing popliteal artery injury.⁶⁸

Dennis et al reported a study of 38 knee dislocations. Two of these patients had hard vascular signs and popliteal artery occlusion on angiography. The remaining dislocations had no hard signs of vascular injury. Fifty percent of these were treated conservatively with no angiography and no adverse sequelae. The remaining patients had selective angiography, revealing intimal defects or narrowing of the popliteal artery, all of which were treated conservatively with no reported complications.⁷³

Some authorities believe that serial physical examinations can obviate the need for arteriography in patients with a knee dislocation that has been reduced and who have a normal physical examination. Doppler pressure measurements may serve as rapid methods for assessing the vascular status. When the ankle/brachial pressure ratio (obtained by dividing the ankle Doppler arterial pressure by the brachial Doppler arterial pressure) is less than 0.8, arteriography should be considered.⁶⁶

The dislocation should be reduced immediately with longitudinal traction after appropriate analgesia and sedation. The reduction is usually accomplished with very little difficulty. The leg should be placed in a long leg posterior splint with 15°-20° of flexion.

Patella Dislocation

The common mechanism of injury for a patella dislocation involves a twisting injury when the foot is planted. The patella can also dislocate following a direct blow.^{27,74} The patella usually dislocates laterally and in many cases will spontaneously relocate. Patients often give a history of the knee "going out of place" and then returning to normal. (Also consider knee dislocation in this scenario.)

If the physical examination reveals only a tender swollen knee and the patella appears to be in place, then the apprehension test may be useful. It is important to evaluate the knee for ligamentous or meniscal injuries, since 12% of patella dislocations will have a concomitant major injury.⁶² Acute hemarthrosis is most commonly seen with an osteochondral fracture or ACL injury. Standard radiographs should be evaluated for avulsion fracture, intraarticular fragments, osteochondral fracture, and patella dislocation.^{4,75,76}

In order to reduce a patella, extend the patient's leg while applying gentle pressure on the patella in the medial direction. Conscious sedation may be required. Once reduced, place the knee in an immobilizer in full extension with ice application for 20 minutes per hour during the first 24 hours. The knee immobilizer should be worn for 3-7 weeks, with progressive weight-bearing as tolerated. Refer the patient to an orthopedist.

Patella Tendon Rupture

Ruptures of the patella tendon usually result from pivoting,

twisting, or a deceleration, such as rebounding in basketball. They are usually associated with other significant ligamentous injuries. On examination, place the knee in 90° of flexion and palpate for a gap in the tendon or a high-riding patella (patella alta). It is important to note that patients with quadriceps or patellar tendon ruptures can still walk. (They have a peculiar forward-leaning gait that allows gravity to extend the knee.) The best way to test the extensor mechanism is to have the patient extend his or her knee against gravity—passive range of motion may be normal. Radiographs may reveal a patella riding high on the femur rather than in its usual location over the knee joint.

Early diagnosis of patellar tendon rupture is important, as undetected injuries can lead to proximal retraction of the patella with resultant quadriceps contraction and adhesions.⁴³ Emergent orthopedics consultation is indicated. (See Figure 10.)

General Treatment Strategies For Knee Injuries

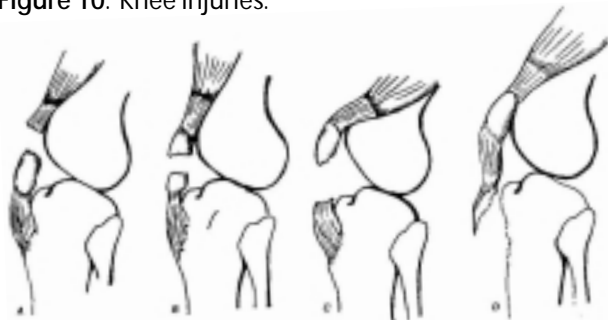After any significant knee injury, protect the knee with a knee immobilizer, placing the knee in 20°-30° of flexion. The RICE mnemonic (rest, ice, compression, and elevation) is generally recommended. Orthopedic referral is indicated for all patients with suspected ligamentous instability or a fracture.⁴²

Arthrocentesis

Arthrocentesis in the setting of an acute injury has limited diagnostic value. Any immediate post-traumatic effusion is assumed to be a hemarthrosis. While fat globules in the aspirate are characteristic of intraarticular fractures, they can also represent significant soft-tissue injury.⁷⁷ In order to visualize the globules, place the aspirate in an emesis basin for a few minutes, allowing the globules to rise to the surface.⁴²

Arthrocentesis may permit better examination of the injured knee. Decompression of a large effusion and instillation of a local anesthetic affords significant pain relief. This relief is only temporary, however, and the hemarthrosis

Figure 10. Knee injuries.



A: Rupture of a quadriceps tendon; B: Fracture of the patella; C: Rupture of the patella tendon; D: Avulsion of the tibial tuberosity.

Reproduced with permission from: Simon R, Koenigskecht S. *Emergency Orthopedics: The Extremities*. New York: McGraw-Hill; 1995:362. Figure 27-4.

tends to recur within the first 24 hours due to the loss of the tamponade effect. The usual treatment of rest, ice, compression, and elevation—especially compression—is important post-arthrocentesis.⁴²

Intraarticular injection of morphine and bupivacaine has been used for its analgesic effect after traumatic knee injuries and elective knee arthroscopy. Recent studies have shown that both drugs reduce the need for systemic analgesia; morphine is more effective and can provide relief for up to 24 hours.^{78,95-97} However, these few studies have all been done in post-operative patients without acute injury. The typical dose is 1-5 mg of morphine (1 mg/mL diluted in normal saline to a total volume of 30 mL), although a more concentrated dose with less volume is a reasonable option.

Achilles Tendon Rupture

Of all spontaneous tendon ruptures, complete Achilles tendon tears are most closely associated with sports activities.⁴⁴ This injury usually occurs with sudden acceleration or jumping, such as in soccer, track and field, basketball, or racquet sports, but it can even occur just by stepping off a curb.⁴⁴ Conditions that predispose to Achilles tendon rupture include rheumatoid arthritis, gout, systemic lupus erythematosus, hyperparathyroidism, chronic renal failure, and corticosteroid or fluoroquinolone use.^{79,80} The patient usually experiences a sudden pop or snap in the foot or ankle with associated pain. The pain may be minimal and resolve spontaneously.

Achilles tendon rupture is missed in up to 25% of patients by the initial examiner,⁸¹ perhaps because patients can still plantar flex (using the toe flexors and other muscles). While the defect in the tendon may be palpated, edema and hemorrhage can quickly obscure the gap. This injury is best assessed using the Thompson's test (also known as the Thompson's squeeze test). The patient is placed prone on the bed with his or her knees flexed to 90° (feet in the air). The calf muscles are squeezed just distal to their widest girth, and the movement of the foot is observed. The absence of plantar flexion of the foot defines a positive test. This was shown to be accurate in 19 of 19 cases in an autopsy series reported by Thompson and Doherty.⁸² While this test can be negative with partial tears, incomplete injuries are thought to be uncommon.

MRI is diagnostic but is usually left to the consultant. Some physicians obtain plain radiographs to exclude a fracture, as associated ankle or foot fractures are sporadically reported.⁸³⁻⁸⁵ Treatment involves casting and/or surgery. It is important to make this diagnosis at the time of initial evaluation, because this can be a debilitating injury if left untreated. If the patient is discharged, splint the foot in plantar flexion and have the patient see the orthopedist within several days.⁶³

Gastrocnemius Strain

Gastrocnemius strain, also known as "tennis leg," is a strain involving the musculotendinous junction of the medial head of the gastrocnemius and the Achilles tendon. The injury occurs following a vigorous propulsive movement

such as a jump or sudden start. The patient reports a pop in the medial upper calf. There is instant pain, and spasm of the calf muscles results in plantar flexion. On examination, there is exquisite point tenderness at the medial junction of the middle and proximal thirds of the calf. Swelling and ecchymosis usually occurs distally. Assess the Achilles tendon function using the Thompson's test. Treatment involves a posterior splint with the foot at 90°. Dorsiflexion must be started within 24 hours post-injury to regain ankle motion.⁴²

Emergency Department Evaluation: Ankle Injuries

The May 2002 issue of *Emergency Medicine Practice*, "Ankle Injuries In The ED: How To Provide Rapid And Cost-Effective Assessment And Treatment," features a full discussion of ankle injuries. Key points concerning sports-related ankle injuries follow.

Ankle sprains are the most common of all ankle injuries (85% of all acute ankle injuries are sprains⁸⁶) and are especially likely to be sustained in sports and recreational activities.⁴³ At present, functional treatment is the rule, and less importance is attributed to differentiating between single and multiple ligament injuries.⁴³ The ankle is often injured during football when a player attempts to change direction quickly on an outside leg that is planted during pivoting. A player's ankle may also be injured by being stepped on.

Some controversy exists regarding the optimal treatment of ankle sprains. A recent systematic review of 12 studies of high methodological quality evaluated functional treatment vs. immobilization. The data favor the functional approach (early mobilization as tolerated) for the following outcomes: return to work and sports, short-term resolution of swelling, and intermediate subjective stability. Immobilized patients were more likely to have impaired range of motion. Patients in the functional management group were more likely to be satisfied with their care in the short and intermediate term and tended to report less pain. No differences were noted between subjective stability or rates of recurrent ankle pain.⁸⁷

Emergency Department Evaluation: Foot Injuries

Anatomy, History, And Physical Examination

The foot is divided into three anatomic regions: the hindfoot, which includes the talus and calcaneus; the midfoot, which includes the navicular, cuboid, and cuneiforms; and the forefoot, which includes the metatarsals, phalanges, and sesamoids. (See Figure 11.)

Determine whether the injury was a result of direct trauma or a torsional force. Ask the patient about the location of the pain, ability to ambulate, as well as previous injuries and operations. A directed physical examination should include inspection for edema and ecchymosis, palpation to localize pain, a neurovascular examination, and range-of-motion examination. *Tenderness over the navicular*

and the base of the fifth metatarsal should be targeted for special attention, as these bones are statistically the most likely injured.⁸⁸

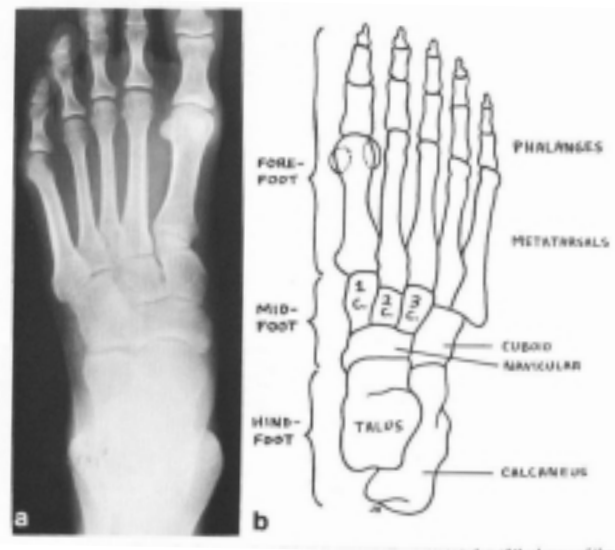
A standard radiographic series of the foot includes AP, lateral, and 45° internal oblique views. Overlapping bones, accessory centers of ossification, and sesamoids can complicate interpretation.⁴

Types Of Injuries

A variety of athletic activities can result in foot injuries. An injury identified with increasing frequency in snowboarders (but difficult to detect on plain radiographs) is fracture of the lateral process of the talus.⁸⁹ The midfoot is also frequently injured, especially the tarsometatarsal joint, also known as Lisfranc's joint. A Lisfranc injury is any injury to this joint or bones contiguous with the joint.⁴³ These injuries can occur in a sport that involves fixation of the forefoot, such as equestrian activity and windsurfing. This injury also occurs in football when the player sustains a blow to the back of the heel, or in baseball while sliding into a base.⁴³

On examination, there is tenderness along the dorsal aspect of the midfoot and variable amounts of swelling. Joint laxity may be present. Spontaneous reduction of this fracture often occurs, resulting in subtle radiographic changes. On the lateral view, look for anatomic alignment of the dorsal margin of the first metatarsal with the lateral cuneiform. AP views should reveal exact alignment of the medial edge of the second metatarsal and intermediate cuneiform. Fractures of the bases of the metatarsals or cuboid fracture suggest severe ligamentous injury as well. Initial management involves splinting and outpatient orthopedic referral to assess the need for surgical repair.⁴³

Figure 11. Foot anatomy.



a: Anteroposterior radiograph of a normal adult foot; b: Schematic representation of the bones of the foot.

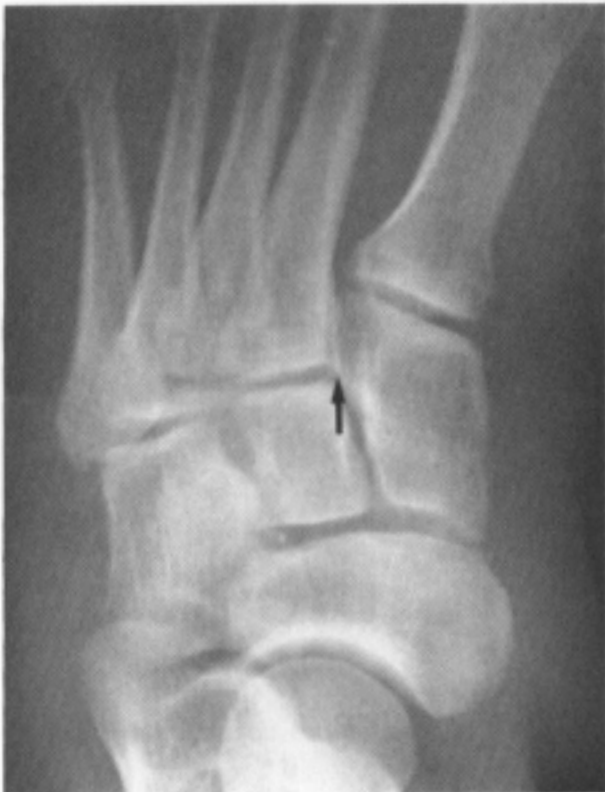Reproduced with permission from: Harris JH Jr, Harris WH. *The Radiology of Emergency Medicine*. 4th ed. Philadelphia: Lippincott, Williams & Wilkins; 2000:868. Figure 1.

(See Figure 12.)

The *Jones fracture* is a transverse fracture at the proximal metaphyseal-diaphyseal junction of the fifth metatarsal. (See Figure 13.) This is commonly confused with a fracture of the tuberosity of the fifth metatarsal base. These are different injuries and require diverse management. The Jones fracture has a significant risk of delayed union or non-union. The mechanism of injury is a load applied to the lateral forefoot without inversion, such as in sports involving running and jumping.⁴ Most metatarsal fractures can be treated with a cast shoe, but the Jones fracture requires splinting and possible surgical management. An acute fracture can be treated by immobilization in a posterior splint with non-weight-bearing and orthopedic referral.⁴

Turf toe refers to a sprain of the first metatarsophalangeal joint. This term was coined in 1976, when the injury was attributed to hard, artificial turf playing surfaces.⁴³ In most cases, the injury occurs as a result of hyperextension (dorsiflexion) of the joint. Examination reveals pain and swelling of the great toe with painful range of motion. Radiographs may show a capsular avulsion fracture involving the first metatarsal head or the base of the proximal phalanx. The mainstay of treatment for this injury is rest, which is difficult to enforce in some athletes. Compression dressing, elevation, and ice are also useful, as well as NSAIDs. Taping the toe to resist dorsiflex-

Figure 12. Lisfranc fracture-dislocation with an avulsion fracture (arrow) of the lateral aspect of the first cuneiform.



Reproduced with permission from: Harris JH Jr, Harris WH. *The Radiology of Emergency Medicine*. 4th ed. Philadelphia: Lippincott, Williams & Wilkins; 2000:885. Figure 46.

ion also helps to relieve pain and control swelling.⁴³ Cortisone or anesthetic injections are not indicated and can prolong recovery.⁹⁰

Special Considerations For Injuries In Young Athletes

Schmidt and Hollwarth compared the frequency of sports injuries in children with their physical location.⁹¹ They found that almost 44% of all injuries involve the upper extremities, 16% involve the head, and 34.5% involve the lower extremities. The peak incidence for injuries is age 12. In general, sprains, contusions, and lacerations account for most injuries. In the lower extremities, the knee joint is the most commonly injured area.^{51,74}

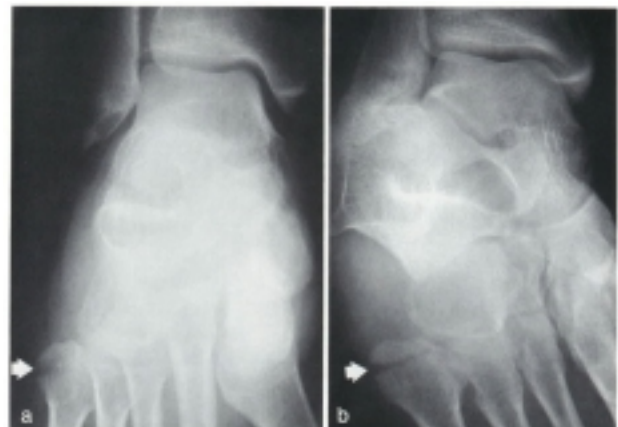
Epiphyseal Injuries

The ligaments and articular capsule are firmer than bone and the epiphyseal plate in children.⁹² As a result, trauma to this region of the maturing skeleton usually injures the cartilaginous epiphyseal plate.⁴ These injuries result from shearing and avulsion forces as well as compression. The cartilaginous cells of the epiphysis may be damaged, resulting in premature closure of the epiphyseal plate and disturbance in bone growth. (See Figure 14 on page 19.)

Upper-Extremity Injuries

The clavicle is the most commonly fractured bone in children.⁸¹ Most of these fractures are greenstick injuries of the midshaft clavicle. Associated neurovascular injury is rare. However, as in adults, posterior displacement of the clavicle from the sternoclavicular joint can cause compression of the trachea or mediastinal vessels. Treatment is sling of the shoulder and analgesia.

Figure 13. Jones fracture.



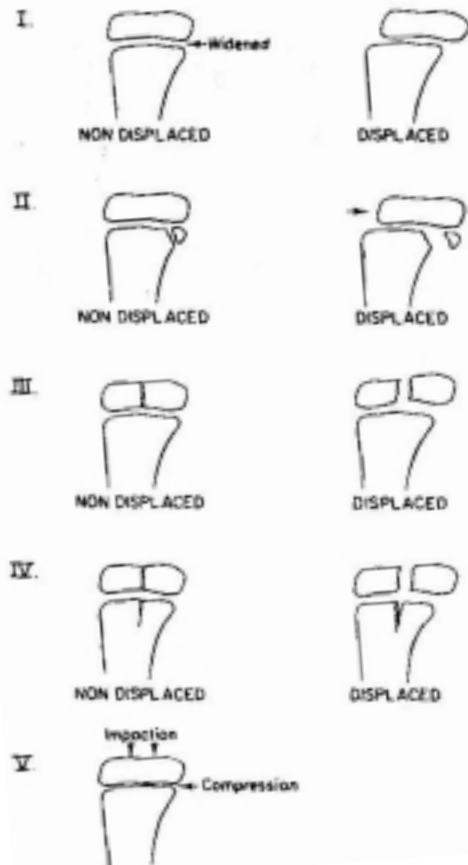
This patient complained of injuring her ankle, and the ankle was examined radiographically. The frontal (a) and internally rotated oblique (b) projections demonstrate the Jones fracture (arrow) of the base of the fifth metatarsal.

Reproduced with permission from: Harris JH Jr, Harris WH. *The Radiology of Emergency Medicine*. 4th ed. Philadelphia: Lippincott, Williams & Wilkins; 2000:883. Figure 40.

GH dislocations are unusual before physal closure. As in adults, most dislocations are anterior. Diagnosis and treatment are the same. Orthopedic referral is essential, as many of these patients can develop chronic instability.

More than 50% of elbow fractures are supracondylar and occur as a result of a fall on an outstretched arm with

Figure 14. Salter-Harris classification of epiphyseal-metaphyseal fractures.



- *Type I:* The epiphyseal line (physis) is widened secondary to some degree of epiphyseal separation. The epiphysis may or may not be displaced.
- *Type II:* There is some large or small metaphyseal fracture fragment in association with widening of the epiphyseal line. The epiphysis and fracture fragment may or may not be visibly displaced.
- *Type III:* In this type, the fracture occurs through the epiphysis and the fracture may or may not be displaced. When displacement occurs, often only part of the fractured epiphysis is displaced.
- *Type IV:* A fracture exists through the epiphysis and the metaphysis; displacement of the fragments may or may not be present.
- *Type V:* An impaction fracture with injury of the epiphyseal plate only is present. No roentgenographic findings other than swelling around the involved epiphyseal-metaphyseal junction usually are present.

Reproduced with permission from: Swischuk LE. *Emergency Imaging of the Acutely Ill or Injured Child*. 4th ed. Philadelphia: Lippincott Williams & Wilkins; 2000. Figure 4.8.

hyperextension at the elbow. Direct vascular injury is uncommon, but the pulse may be diminished secondary to arterial spasm. Neurologic deficits are usually transient but can be due to direct nerve injury. Emergent orthopedic consultation is usually required for these injuries. Forearm compartment syndrome is a feared complication.

The elbow is dislocated more often than any other major joint in children and adolescents, but it is still an unusual injury. Associated fractures are common. Neurovascular examination is important to evaluate for ulnar nerve and brachial artery injury.⁸¹

Hip/Pelvis Injuries

The presence of unfused epiphyses predisposes the pediatric hip and pelvis to traction injuries. Large fragments of bone can be avulsed with sudden and unexpected loads. The anterior superior iliac spine can be avulsed during football when the kicking foot is suddenly blocked or tackled. The psoas muscle can also avulse off of the lesser trochanter. The whole apophyseal plate of the ischium can separate via a pull of the hamstrings. This can be caused by overstretching the leading leg while running. Treatment for any of these injuries is conservative, and surgery is rarely needed.⁵⁵

Knee Injuries

An avulsion injury may mimic a tear of the ACL. The ACL remains intact, but a large piece of the proximal tibia is avulsed secondary to flexion, twisting, or hyperextension.

In pediatric knee injuries, radiographs may be normal, but be suspicious of a significant injury if the knee is unstable. An unwary emergency physician may mistake a tibial tubercle for an avulsion fracture. Meniscal problems in this age group are uncommon.⁵⁵

Physal fractures in the region of the knee may be associated with ligamentous injuries.⁴ Immobilization and prompt orthopedic referral are mandatory.

Ankle Injuries

The twisting injuries that cause a fracture in adults produce a different pattern of injury in the immature skeleton. Inversion trauma to the ankle of a skeletally immature patient frequently causes separation of the distal fibular physis and spares the lateral ligaments. Physal fractures are commonly misdiagnosed as ankle sprains, because spontaneous reduction usually occurs and radiographs reveal no bony abnormality.⁴³ In general, ankle fractures in children are minimally displaced. However, when they involve the articular surface, they may require surgery.

Conclusion

While sports injuries are common, they do present several distinct challenges to the emergency physician. Above all, the emergency physician must accurately determine whether the injury is stable or unstable. This key determination drives further management, including the type of follow-up and referral that are necessary. Knowing which types of serious injuries can masquerade as seemingly

trivial injuries will serve the patient and physician alike.

Radiography associated with orthopedic sports injuries is costly, and the films are often negative. Important aspects of the history and physical examination, including some physical examination maneuvers, can help obviate the need for radiography under some circumstances—and increase the index of suspicion for serious injury in others. Clinical decision rules such as the Ottawa ankle rules, Ottawa knee rules, and Pittsburgh knee rules are medically appropriate and cost-effective. ▲

References

Evidence-based medicine requires a critical appraisal of the literature based upon study methodology and number of subjects. Not all references are equally robust. The findings of a large, prospective, randomized, and blinded trial should carry more weight than a case report.

To help the reader judge the strength of each reference, pertinent information about the study, such as the type of study and the number of patients in the study, will be

Ten Pitfalls To Avoid

1. "He said that he just turned his ankle. He didn't mention hearing a pop. I didn't think he would have an Achilles injury."

All patients with an ankle or foot injury should have their Achilles tendon examined for injury, as this can present in a similar manner as an ankle sprain. This is often a surgically correctable injury that must not be missed.

2. "I know she was in too much pain to let me stress her knee, but it seemed like a simple knee strain. I didn't think she needed referral to an orthopedist."

Internal derangements of the knee may be difficult to diagnose in the acute setting because of pain and edema. A conservative approach of referral is usually warranted in any patient in whom an internal derangement is suspected.

3. "I'm pretty sure that he broke his humeral head as a result of the fall that caused his shoulder dislocation. I really don't think I did it as a result of the reduction."

Yes, but you can't prove it. Whenever possible, obtain a radiograph of a patient with a suspected shoulder dislocation before attempting reduction. The physician should attempt a "blind" reduction only if there is evidence of serious neurovascular compromise and if there will be a significant delay in obtaining a radiograph.

4. "I didn't think he had a knee dislocation. His knee joint appeared normal on x-ray."

Many knee dislocations reduce spontaneously prior to evaluation by a physician, and all that remains is edema and ligamentous instability. Consider the mechanism of injury (especially high-energy injuries) and the patient's history with regards to the appearance of the knee just after the injury. Document a thorough neurovascular examination (including ankle/brachial index in the case of significant trauma) and always consider a popliteal artery injury. Assume a dislocation if the knee is grossly unstable on examination.

5. "You manage a Jones fracture the same as any other metatarsal fracture—with a cast shoe. Right?"

Wrong. These injuries have a higher incidence of

complications such as nonunion and need to be immobilized properly with a posterior splint and referred to an orthopedist in a timely manner.

6. "He said he had knee pain. His knee exam was normal, so I diagnosed him with a strain and discharged him."

Hip disorders can cause referred knee pain and should be considered in any patient with knee pain and a normal knee examination. Even if there is no complaint of hip pain, the hip should be examined, and this should be documented.

7. "Her shoulder series of radiographs was normal. The technician forgot to do an axillary view, but I didn't think it was important."

Sometimes the only way to diagnose a posterior shoulder dislocation is via an axillary (or scapular-Y) view. This is an important injury that cannot be missed. It is the responsibility of the ordering physician to be sure that an appropriate series of radiographs is obtained.

8. "He was too sleepy after the conscious sedation I gave him to reduce his elbow dislocation. He didn't complain of any numbness or weakness in his hand."

Ulnar nerve entrapment should be considered after reduction of an elbow dislocation. The patient may not volunteer that he or she has ulnar nerve distribution numbness and weakness. This needs to be tested and documented before and after the reduction.

9. "His x-rays were normal. I didn't think he broke his ankle. Sure, he couldn't bear weight on it, but he's just a kid. They heal quickly, right?"

In children, fractures are more common than sprains. Some Salter-Harris injuries are difficult to detect on initial radiograph. Use caution and assume a fracture to be present; then treat it accordingly.

10. "How could he have ruptured his quadriceps muscle? He was able to walk, and I could move his knee without any problem."

Patients with rupture of the extensor mechanism of the knee can still walk and have normal passive range of motion—they just cannot extend the knee against gravity. ▲

included in bold type following the reference, where available. In addition, the most informative references cited in the paper, as determined by the authors, will be noted by an asterisk (*) next to the number of the reference.

1. No authors listed. Nonfatal sports- and recreation-related injuries treated in emergency departments—United States, July 2000-June 2001. *MMWR Morb Mortal Wkly Rep* 2002 Aug 23;5(33):736-740. **(Epidemiological data)**
2. Bleakely C, MacAuley D. The quality of research in sports journals. *Br J Sports Med* 2002;36(2):124-125. **(Review)**
3. Owen S, Itamura JM. Differential diagnosis of shoulder injuries in sports. *Orthop Clin North Am* 2001;32(3):393-398. **(Review)**
4. Marx JA, Hockberger RS, Walls RH, et al, eds. *Rosen's Emergency Medicine*. 5th ed. St. Louis: Mosby; 2002. **(Textbook)**
5. Fraenkel L, Shearer P, Mitchell P, et al. Improving the selective use of plain radiographs in clinically evident anterior shoulder dislocation. *Am J Emerg Med* 1999;17(7):653-658. **(Prospective; 206 patients)**
6. Shuster M, Abu-Laban RB, Boyd J. Prereduction radiographs in clinically evident anterior shoulder dislocation. *Am J Emerg Med* 1999;17(7):653-658. **(Prospective; 97 patients)**
7. Hendeby GW, Kinlaw K. Clinically significant abnormalities in post-reduction radiographs after anterior shoulder dislocation. *Ann Emerg Med* 1996;28(4):399-402. **(Retrospective; 175 patients)**
8. Williams RJ. Significant pneumothorax complicating a fractured clavicle. *J Accid Emerg Med* 1995;12(3):218-219. **(Case report)**
9. Post M. Current concepts in the treatment of fractures of the clavicle. *Clin Orthop* 1989;245:89-101. **(Review)**
- 10.* Blake R, Hoffman J. Emergency department evaluation and treatment of the shoulder and humerus. *Emerg Med Clin North Am* 1999;17(4):859-876. **(Review)**
11. Anderson K, Jenson PO. Treatment of clavicle fracture: figure of 8 bandage vs. simple sling. *Acta Orthop Scand* 1987;58(1):71-74. **(Prospective; 79 patients)**
12. McLaughlin JA, Light R, Lustrin I. Axillary artery injury as a complication of proximal humerus fractures. *J Shoulder Elbow Surg* 1998 May-Jun;7(3):292-294. **(Case report)**
13. Bossart PJ, Joyce SM, Manaster BJ, et al. Lack of efficacy of 'weighted' radiographs in diagnosing acute acromioclavicular separation. *Ann Emerg Med* 1988 Jan;17(1):20-24. **(Comparative, randomized, controlled trial; 83 patients)**
14. Tzannes A, Murrell GA. Clinical examination of the unstable shoulder. *Sports Med* 2002;32(7):447-457. **(Review)**
15. Ghafil D, Putz P. Subnormal functional activity in a neglected posterior dislocation of the shoulder. *Acta Orthop Belg* 1998;64(3):339-342. **(Case report)**
16. Perlmutter GS. Axillary nerve injury. *Clin Orthop* 1999;368:28-36. **(Review)**
17. Perlmutter GS, Apruzzese W. Axillary nerve injuries in contact sports: recommendations for treatment and rehabilitation. *Sports Med* 1998;26(5):351-361. **(Review)**
18. Grate I. Luxatio erecta: a rarely seen but often missed shoulder dislocation. *Am J Emerg Med* 2000;18(3):317-321. **(Case series)**
19. Kosnik KJ, Shamsa F, Raphael E, et al. Anesthetic methods for reduction of acute shoulder dislocations: a prospective randomized study comparing intraarticular lidocaine with intravenous analgesia and sedation. *Am J Emerg Med* 1999;17(6):566-570. **(Prospective, randomized, controlled trial; 49 patients)**
20. Matthews PE, Roberts J. Intraarticular lidocaine versus intravenous analgesia for reduction of acute anterior shoulder dislocation. *Am J Sports Med* 1995;23(1):54-58. **(Prospective; 30 patients)**
21. Miller SL, Cleeman E, Auerbach J, et al. Comparison of intra-articular lidocaine and intravenous sedation for reduction of shoulder dislocations. *J Bone Joint Surg* 2002;84:2135-2139. **(Prospective; 30 patients)**
22. Rowe CR. Acute and recurrent anterior dislocations of the shoulder. *Orthop Clin North Am* 1980;2:253-270. **(Review)**
23. Johnson G, Hulse W, McGowan A. The Milch technique for reduction of anterior shoulder dislocations in an accident and emergency department. *Arch Emerg Med* 1992 Mar;9(1):40-43. **(Retrospective; 187 patients)**
- 24.* McNamara RM. Reduction of anterior shoulder dislocations by scapular manipulation. *Ann Emerg Med* 1993 Jul;22(7):1140-1144. **(Prospective, 54 patients)**
25. Yuen MC, Yap PG, Chan XT, et al. An easy method to reduce anterior shoulder dislocation: the Spaso technique. *Emerg Med J* 2001;18(5):370-372. **(Prospective; 16 patients)**
26. Wen D. Current concepts in the treatment of anterior shoulder dislocations. *Am J Emerg Med* 1999;17(4):401-407. **(Review)**
27. Tintinalli JE, Kelen GD, Stapczynski JS. *Emergency Medicine: A Comprehensive Study Guide*. 5th ed. New York: McGraw-Hill; 2000. **(Textbook)**
28. Litaker D, Pioro M, El Bilbeisi H, et al. Returning to the bedside: using history and physical examination to identify rotator cuff tears. *J Am Geriatr Soc* 2000;48(12):1633-1637. **(Retrospective; 448 patients)**
29. Patton WC, McCluskey GM 3rd. Biceps tendinitis and subluxation. *Clin Sports Med* 2001 Jul;20(3):505-529. **(Review)**
30. Curtis AS, Snyder SJ. Evaluation and treatment of biceps tendon pathology. *Orthop Clin North Am* 1993 Jan;24(1):33-43. **(Review)**
31. Lee SJ, Montgomery K. Athletic hand injuries. *Orthop Clin North Am* 2002 Jul;33(3):547-554. **(Review)**
32. Graham TJ. Hand. In: Beatty JH, ed. *Orthopaedic Knowledge Update 6: Home Study Syllabus*. Rosemont, IL: American Academy of Orthopaedic Surgeons; 1999. **(Textbook)**
33. Frohna WJ. Emergency department evaluation and treatment of the neck and cervical spine injuries. *Emerg Med Clin North Am* 1999 Nov;17(4):739-791, v. **(Review)**
34. Koffler KM, Kelly JD 4th. Neurovascular trauma in athletes. *Orthop Clin North Am* 2002 Jul;33(3):523-534, vi. **(Review)**
- 35.* Cantu RC, Bailes JE, Wilberger JE, et al. Guidelines for return to contact or collision sport after a cervical spine injury. *Clin Sports Med* 1998;17(1):137-146. **(Review)**
36. Torg JS, Pavlov H, Genuario SE, et al. Neurapraxia of the cervical spinal cord with transient quadriplegia. *J Bone Joint Surg Am* 1986 Dec;68(9):1354-1370. **(Comparative; 81 patients)**
37. Matsuura P, Waters RL, Adkins RH, et al. Comparison of computerized tomography parameters of the cervical spine in normal control subjects and spinal cord-injured patients. *J Bone Joint Surg Am* 1989 Feb;71(2):183-188. **(Prospective; 142 patients)**
38. Nugent GR. Clinicopathological correlations in cervical spondylosis. *Neurology* 1959;9:273-281. **(Review)**
39. Hildebrand KA, Patterson SD, King JG. Acute elbow dislocations: simple and complex. *Orthop Clin North Am* 1999;30(1):63-79. **(Review)**
40. Anderson MK, Hall SJ. *Sports Injury Management*. Baltimore: Williams & Wilkins; 1995 **(Textbook)**
41. Platz A, Heinzelmann M, Ertel W, et al. Posterior elbow dislocation with associated vascular injury after blunt trauma. *J Trauma* 1999;46(5):948-950. **(Retrospective; 4 patients)**
42. Garrick JG, Webb DR. *Sports Injuries: Diagnosis and Management*. 2nd ed. Philadelphia: W.B. Saunders; 1999. **(Textbook)**
43. Baker CL, ed. *The Hughston Clinic Sports Medicine Book*. Baltimore: Williams & Wilkins; 1995. **(Textbook)**
44. Kannus P, Natri A. Etiology and pathophysiology of tendon ruptures in sports. *Scand J Med Sci Sports* 1997 Apr;7(2):107-112. **(Retrospective; 430 patients)**
45. Ransey RH, Muller GE. Quadriceps tendon rupture: a diagnostic trap. *Orthopedics* 1970;70:161. **(Review)**
46. Verma A, Su A, Golin AM, et al. A screening method for knee trauma. *Acad Radiol* 2001 May;8(5):392-397. **(Prospective; 214 patients)**
47. Stevermer JJ, Chambliss ML. Validation of decision rules for radiography in knee injuries. *J Fam Pract* 1996 Jun;42(6):564-565. **(Prospective; 1096 patients)**
48. Chen E, Maffulli N, Chan KM. Knee injuries produced by recreational sports follow a different pattern than casual injuries. *Bull Hosp Jt Dis* 1998;57(2):74-79. **(Prospective; 208 patients)**
49. Solomon DH, Simel DL, Bates DW, et al. The rational clinical examination. Does this patient have a torn meniscus or ligament of the knee? Value of the physical examination. *JAMA* 2001 Oct 3;286(13):1610-1620. **(Review)**
50. Swenson TM. Physical diagnosis of the multiple-ligament-injured knee. *Clin Sports Med* 2000 Jul;19(3):415-423. **(Review)**
- 51.* Roberts DM, Stallard TC. Emergency department evaluation and treatment of knee and leg injuries. *Emerg Med Clin North Am* 2000

- Feb;18(1):67-84, v-vi. **(Review)**
52. Beatty JH, ed. *Orthopaedic Knowledge Update 6: Home Study Syllabus*. Rosemont, IL: American Academy of Orthopaedic Surgeons; 1999. **(Textbook)**
 53. Sonzogni JJ. Examining the injured knee. *Emerg Med* 1996;28:78-86. **(Review)**
 54. Rubinstein RA Jr, Shelbourne KD, McCarroll JR, et al. The accuracy of the clinical examination in the setting of posterior cruciate ligament injuries. *Am J Sports Med* 1994 Jul-Aug;22(4):550-557. **(Prospective, randomized, controlled trial; 39 patients)**
 55. Hackney R, Wallace A, eds. *Sports Medicine Handbook*. London: BMJ Publishing Group; 1999. **(Textbook)**
 - 56.* Stiell IG, Greenberg GH, Wells GA, et al. Derivation of a decision rule for the use of radiography in acute knee injuries. *Ann Emerg Med* 1995 Oct;26(4):405-413. **(Prospective survey; 1047 patients)**
 57. Emparanza JI, Aginaga JR. Estudio Multicéntrico en Urgencias de Osakidetza: Reglas de Ottawa (EMUORO) Group. *Ann Emerg Med* 2001 Oct;38(4):364-368. **(Prospective validation study; 1522 patients)**
 58. Tigges S, Pitts S, Mukundan S Jr, et al. External validation of the Ottawa knee rules in an urban trauma center in the United States. *AJR Am J Roentgenol* 1999 Apr;172(4):1069-1071. **(Prospective; 378 patients)**
 - 59.* Stiell IG, Greenberg GH, Wells GA, et al. Prospective validation of a decision rule for the use of radiography in acute knee injuries. *JAMA* 1996 Feb 28;275(8):611-615. **(Prospective survey; convenience sample of 1096 of 1251 eligible adults with acute knee injuries; 124 patients were examined by two physicians)**
 60. Seaberg DC, Yealy DM, Lukens T, et al. Multicenter comparison of two clinical decision rules for the use of radiography in acute, high-risk knee injuries. *Ann Emerg Med* 1998 Jul;32(1):8-13. **(Prospective, blinded, multicenter; 934 patients)**
 61. Khine H, Dorfman DH, Avner JR. Applicability of Ottawa knee rule for knee injury in children. *Pediatr Emerg Care* 2001 Dec;17(6):401-404. **(Prospective, 234 patients)**
 62. Laskowski ER. Snow skiing. *Phys Med Rehabil Clin N Am* 1999 Feb;10(1):189-211. **(Review)**
 - 63.* Roberts JR. *Roberts' Practical Guide to Common Medical Emergencies*. Philadelphia: Lippincott-Raven; 1996:211-219. **(Textbook)**
 64. Roman PD, Hopson CN, Zenni EJ Jr. Traumatic dislocation of the knee: a report of 30 cases and literature review. *Orthop Rev* 1987 Dec;16(12):917-924. **(Clinical trial, review)**
 65. Wascher DC, Dvirnak PC, DeCoster TA. Knee dislocation: initial assessment and implications for treatment. *J Orthop Trauma* 1997 Oct;11(7):525-529. **(Retrospective; 50 patients)**
 66. Potter HG. Imaging of the multiple-ligament-injured knee. *Clin Sports Med* 2000 Jul;19(3):425-441. **(Review)**
 67. Kendall RW, Taylor DC, Salvian AJ, et al. The role of arteriography in assessing vascular injuries associated with dislocations of the knee. *J Trauma* 1993 Dec;35(6):875-878. **(Retrospective; 35 patients)**
 - 68.* Miranda FE, Dennis JW, Veldenz HC, et al. Confirmation of the safety and accuracy of physical examination in the evaluation of knee dislocation for injury of the popliteal artery: a prospective study. *J Trauma* 2002 Feb;52(2):247-251; discussion 251-252. **(Prospective; 35 patients)**
 69. Melton SM, Croce MA, Patton JH Jr, et al. Popliteal artery trauma. Systemic anticoagulation and intraoperative thrombolysis improves limb salvage. *Ann Surg* 1997 May;225(5):518-527; discussion 527-529. **(Follow-up study; 102 patients)**
 70. Rose SC, Moore EE. Trauma angiography: the use of clinical findings to improve patient selection and case preparation. *J Trauma* 1988 Feb;28(2):240-245. **(Retrospective; 280 patients)**
 71. Bryan T, Merritt P, Hack B. Popliteal arterial injuries associated with fractures or dislocations about the knee as a result of blunt trauma. *Orthop Rev* 1991 Jun;20(6):525-530. **(Retrospective; 73 patients)**
 72. Gable DR, Allen JW, Richardson JD. Blunt popliteal artery injury: is physical examination alone enough for evaluation? *J Trauma* 1997 Sep;43(3):541-544. **(Review)**
 73. Dennis JW, Jagger C, Butcher JL, et al. Reassessing the role of arteriograms in the management of posterior knee dislocations. *J Trauma* 1993 Nov;35(5):692-695; discussion 695-697. **(Retrospective; 37 patients)**
 74. Bruns W, Maffulli N. Lower limb injuries in children in sports. *Clin Sports Med* 2000 Oct;19(4):637-662. **(Review)**
 75. Krodel A, Refior HJ. Patellar dislocation as a cause of osteochondral fracture of the femoro-patellar joint. *Unfallchirurgie* 1990 Feb;16(1):12-17. German. **(Retrospective; 78 patients)**
 76. Nietosvaara Y, Aalto K, Kallio PE. Acute patellar dislocation in children: incidence and associated osteochondral fractures. *J Pediatr Orthop* 1994 Jul-Aug;14(4):513-515. **(Prospective; 72 patients)**
 77. Gregg JR, Nixon JE, DiStefano V. Neutral fat globules in traumatized knees. *Clin Orthop* 1978 May;(132):219-224. **(Prospective; 146 patients)**
 78. VanNess SA, Gittins ME. Comparison of intra-articular morphine and bupivacaine following knee arthroscopy. *Orthop Rev* 1994 Sep;23(9):743-747. **(Prospective; 81 patients)**
 79. Kao NL, Moy JN, Richmond GW. Achilles tendon rupture: an underrated complication of corticosteroid treatment. *Thorax* 1992 Jun;47(6):484. **(Letter)**
 80. Huston KA. Achilles tendinitis and tendon rupture due to fluoroquinolone antibiotics. *N Engl J Med* 1994 Sep 15;331(11):748. **(Letter)**
 81. Landvater SJ, Renstrom PA. Complete Achilles tendon ruptures. *Clin Sports Med* 1992 Oct;11(4):741-758. **(Review)**
 82. Thompson TC, Doherty JH. Spontaneous rupture of tendon of Achilles: a new clinical diagnostic test. *J Trauma* 1962 Mar;2:126-129. **(Case series)**
 83. Lubin JW, Miller RA, Robinson BJ, et al. Achilles tendon rupture associated with ankle fracture. *Am J Orthop* 2000 Sep;29(9):707-708. **(Case report)**
 84. Assal M, Stern R, Peter R. Fracture of the ankle associated with rupture of the Achilles tendon: case report and review of the literature. *J Orthop Trauma* 2002 May;16(5):358-361. **(Review, case report)**
 85. Martin JW, Thompson GH. Achilles tendon rupture. Occurrence with a closed ankle fracture. *Clin Orthop* 1986 Sep;(210):216-218. **(Case report)**
 86. Garrick JG. The frequency of injury, mechanism of injury, and epidemiology of ankle sprains. *Am J Sports Med* 1977 Nov-Dec;5(6):241-242. **(Retrospective; 2840 patients)**
 87. Kerkhoffs GM, Rowe BH, Assendelft WJ, et al. Immobilisation for acute ankle sprain. A systematic review. *Arch Orthop Trauma Surg* 2001 Sep;121(8):462-471. **(Literature review; 22 studies)**
 88. Stiell IG, Greenberg GH, McKnight RD, et al. Decision rules for the use of radiography in acute ankle injuries. Refinement and prospective validation. *JAMA* 1993 Mar 3;269(9):1127-1132. **(Prospective survey; validation and refinement of the original rules (first stage) and validation of the refined rules (second stage); 1032 patients in the first stage, 453 patients in the second stage)**
 89. Janes PC, Paul C. The snowboarder's talus fracture. The 10th international symposium on skiing trauma and safety. Zellam See, Austria, May 1993. **(Review)**
 90. Wedmore IS, Charette J. Emergency department evaluation and treatment of ankle and foot injuries. *Emerg Med Clin North Am* 2000 Feb;18(1):85-113, vi. **(Review)**
 91. Schmidt B, Hollwarth ME. Sports accidents in children and adolescents. *Z Kinderchir* 1989;44(6):357-362. **(Retrospective; 2617 patients)**
 92. Spongeller P, Beatty JH. Fractures and dislocations about the knee. In: *Fractures in Children*. 4th ed. Philadelphia: Lippincott-Raven; 1996. **(Textbook)**
 - 93.* MacAuley D. Ice therapy: how good is the evidence? *Int J Sports Med* 2001 Jul;22(5):379-384. **(Review)**
 - 94.* MacAuley D. Do textbooks agree on their advice on ice? *Clin J Sport Med* 2001 Apr;11(2):67-72. **(Review)**
 95. Guler G, Karaoglu S, Velibasoglu H, et al. Comparison of analgesic effects of intra-articular tenoxicam and morphine in anterior cruciate ligament reconstruction. *Knee Surg Sports Traumatol Arthrosc* 2002 Jul;10(4):229-232. **(Randomized, controlled trial; 42 patients)**
 96. Ho ST, Wang TJ, Tang JS, et al. Pain relief after arthroscopic knee surgery: intravenous morphine, epidural morphine, and intra-articular morphine. *Clin J Pain* 2000 Jun;16(2):105-109. **(Randomized, controlled trial; 75 patients)**
 97. Lundin O, Rydgren B, Sward L, et al. Analgesic effects of intra-

articular morphine during and after knee arthroscopy: a comparison of two methods. *Arthroscopy* 1998 Mar;14(2):192-196.

(Randomized, controlled trial; 50 patients)

98. Neer CS. Impingement lesions. *Clin Orthop* 1983;173:70-77. **(Review)**

Physician CME Questions

49. Patients with low-risk shoulder injuries include:

- those with no fall and no swelling.
- those with a fall but no swelling or pain at rest.
- those with a fall and pain at rest but no swelling and normal range of motion.
- any of the above.
- none of the above.

50. Two-part proximal humeral fracture-dislocations should be reduced in the ED.

- True
- False

51. All of the following are true about clavicle fractures except:

- They usually result from a direct blow to the clavicle or a fall on an outstretched arm.
- Pneumothorax is a common complication of clavicle fracture.
- Most clavicle fractures occur in the middle third of the clavicle.
- Randomized, controlled clinical trials show equivalent outcomes with figure-of-eight clavicle straps and simple slings for middle-third clavicle fractures.

52. The appropriate disposition of patients with glenoid fractures is:

- immobilization and orthopedic referral within three days.
- urgent orthopedic consultation.
- urgent surgical consultation.
- discharge home with the RICE regimen and NSAIDs.

53. Reduction of glenohumeral dislocations:

- requires orthopedic consultation in the vast majority of cases.
- generally requires conscious sedation.
- can often be performed with intraarticular lidocaine, which shortens ED stays and reduces costs significantly, instead of conscious sedation.
- does not require orthopedic follow-up in children.

54. All of the following are true about "jersey finger" except:

- It is a rupture of the extensor tendon that attaches to the dorsal side of the distal phalanx of the finger.
- It is a tear of the flexor digitorum profundus.
- The physical examination is diagnostic of this injury.
- The finger should be splinted with the finger and wrist flexed and urgently referred to a hand specialist for operative management.

55. Rotator cuff tears:

- are usually acute.
- can be identified by supra- and infraspinatus atrophy, weakness with elevation or external rotation of the shoulder, or the impingement sign.
- require MRI for ED diagnosis.
- usually don't require analgesia.

56. The unilaterality, brevity, and pain-free range of motion in the athlete can assist in discriminating between a "stinger" and a cervical cord injury.

- True
- False

57. The sport most likely to result in an elbow dislocation is:

- gymnastics.
- tennis.
- football.
- weight-lifting.

58. A "hip pointer":

- is a contusion of the iliac crest.
- may result in severe disability because the iliac crest serves as an anchor for abdominal and hip musculature.
- usually results from a direct blow to the hip.
- is treated with ice, analgesics, and possibly a six- to eight-day steroid burst to reduce the duration of disability.
- all of the above.

59. ACL tears and meniscal injuries are more likely to result from sports injuries than other mechanisms.

- True
- False

60. The Lachman test evaluates the ACL and is the single best clinical test for determining the integrity of the ACL.

- True
- False

61. All of the following are part of the Ottawa knee rules except:

- the patient is 55 years or older.
- there is tenderness at the head of the fibula or isolated tenderness of the patella.
- the patient is unable to flex the knee to 90°.
- the patient is unable to take four steps both at the time of injury and at time of evaluation.
- the injury is more than seven days old.

62. Meniscal injuries:

- classically involve joint line pain, swelling, and locking.
- can be ruled out by a negative McMurray test.
- require urgent orthopedic consultation.
- can be ruled out if the knee has been fractured or displaced.

63. In orthopedic foot injuries, the navicular and the base of the fifth metatarsal are statistically the least likely to be injured.

- a. True
- b. False

64. All of the following are true about sports injuries in children except:

- a. The ligaments and articular capsule are firmer than bone and the epiphyseal plate.
- b. 44% of all injuries involve the upper extremities, 16% involve the head, and 34.5% involve the lower extremities.
- c. In contrast to adults, trauma in children is more likely to injure the cartilaginous epiphyseal plate than ligaments.
- d. Epiphyseal injuries are unlikely to disturb future bone growth.

Class Of Evidence Definitions

Each action in the clinical pathways section of *Emergency Medicine Practice* receives an alpha-numerical score based on the following definitions.

Class I

- Always acceptable, safe
- Definitely useful
- Proven in both efficacy and effectiveness

Level of Evidence:

- One or more large prospective studies are present (with rare exceptions)
- High-quality meta-analyses
- Study results consistently positive and compelling

Class II

- Safe, acceptable
- Probably useful

Level of Evidence:

- Generally higher levels of evidence
- Non-randomized or retrospective studies: historic, cohort, or case-control studies
- Less robust RCTs
- Results consistently positive

Class III

- May be acceptable
- Possibly useful
- Considered optional or alternative treatments

Level of Evidence:

- Generally lower or intermediate levels of evidence

- Case series, animal studies, consensus panels
- Occasionally positive results

Indeterminate

- Continuing area of research
- No recommendations until further research

Level of Evidence:

- Evidence not available
- Higher studies in progress
- Results inconsistent, contradictory
- Results not compelling

Significantly modified from: The Emergency Cardiovascular Care Committees of the American Heart Association and representatives from the resuscitation councils of ILCOR: How to Develop Evidence-Based Guidelines for Emergency Cardiac Care: Quality of Evidence and Classes of Recommendations; also: Anonymous. Guidelines for cardiopulmonary resuscitation and emergency cardiac care. Emergency Cardiac Care Committee and Subcommittees, American Heart Association. Part IX. Ensuring effectiveness of community-wide emergency cardiac care. *JAMA* 1992;268(16):2289-2295.

Physician CME Information

This CME enduring material is sponsored by Mount Sinai School of Medicine and has been planned and implemented in accordance with the Essentials and Standards of the Accreditation Council for Continuing Medical Education. Credit may be obtained by reading each issue and completing the printed post-tests administered in December and June or online single-issue post-tests administered at www.empractice.net.

Target Audience: This enduring material is designed for emergency medicine physicians.

Needs Assessment: The need for this educational activity was determined by a survey of medical staff, including the editorial board of this publication; review of morbidity and mortality data from the CDC, AHA, NCHS, and ACEP; and evaluation of prior activities for emergency physicians.

Date of Original Release: This issue of *Emergency Medicine Practice* was published April 1, 2003. **This activity is eligible for CME credit through April 1, 2006.** The latest review of this material was March 7, 2003.

Discussion of Investigational Information: As part of the newsletter, faculty may be presenting investigational information about pharmaceutical products that is outside Food and Drug Administration approved labeling. Information presented as part of this activity is intended solely as continuing medical education and is not intended to promote off-label use of any pharmaceutical product. **Disclosure of Off-Label Usage:** This issue of *Emergency Medicine Practice* discusses no off-label use of any pharmaceutical product.

Faculty Disclosure: In compliance with all ACCME Essentials, Standards, and Guidelines, all faculty for this CME activity were asked to complete a full disclosure statement. The information received is as follows: Dr. Freeman, Dr. Corley, Dr. Daya, and Dr. Della-Giustina report no significant financial interest or other relationship with the manufacturer(s) of any commercial product(s) discussed in this educational presentation.

Accreditation: Mount Sinai School of Medicine is accredited by the Accreditation Council for Continuing Medical Education to sponsor continuing medical education for physicians.

Credit Designation: Mount Sinai School of Medicine designates this educational activity for up to 4 hours of Category 1 credit toward the AMA Physician's Recognition Award. Each physician should claim only those hours of credit actually spent in the educational activity. *Emergency Medicine Practice* is approved by the American College of Emergency Physicians for 48 hours of ACEP Category 1 credit (per annual subscription). *Emergency Medicine Practice* has been reviewed and is acceptable for up to 48 Prescribed credit hours by the American Academy of Family Physicians. *Emergency Medicine Practice* has been approved for 48 Category 2-B credit hours by the American Osteopathic Association.

Earning Credit: Two Convenient Methods

- **Print Subscription Semester Program:** Paid subscribers with current and valid licenses in the United States who read all CME articles during each *Emergency Medicine Practice* six-month testing period, complete the post-test and the CME Evaluation Form distributed with the December and June issues, and return it according to the published instructions are eligible for up to 4 hours of Category 1 credit toward the AMA Physician's Recognition Award (PRA) for each issue. You must complete both the post-test and CME Evaluation Form to receive credit. Results will be kept confidential. CME certificates will be delivered to each participant scoring higher than 70%.
- **Online Single-Issue Program:** Paid subscribers with current and valid licenses in the United States who read this *Emergency Medicine Practice* CME article and complete the online post-test and CME Evaluation Form at www.empractice.net are eligible for up to 4 hours of Category 1 credit toward the AMA Physician's Recognition Award (PRA). You must complete both the post-test and CME Evaluation Form to receive credit. Results will be kept confidential. CME certificates may be printed directly from the Web site to each participant scoring higher than 70%.

Emergency Medicine Practice is not affiliated with any pharmaceutical firm or medical device manufacturer.

Publisher: Robert Williford. **Executive Editor:** Heidi Frost.

Direct all editorial or subscription-related questions to EB Practice, LLC: 1-800-249-5770 • Fax: 1-770-500-1316 • Non-U.S. subscribers, call: 1-678-366-7933

EB Practice, LLC • 305 Windlake Court • Alpharetta, GA 30022

E-mail: emp@empractice.net • Web Site: <http://www.empractice.net>

Emergency Medicine Practice (ISSN 1524-1971) is published monthly (12 times per year) by EB Practice, LLC, 305 Windlake Court, Alpharetta, GA 30022. Opinions expressed are not necessarily those of this publication. Mention of products or services does not constitute endorsement. This publication is intended as a general guide and is intended to supplement, rather than substitute, professional judgment. It covers a highly technical and complex subject and should not be used for making specific medical decisions. The materials contained herein are not intended to establish policy, procedure, or standard of care. *Emergency Medicine Practice* is a trademark of EB Practice, LLC. Copyright ©2003 EB Practice, LLC. All rights reserved. No part of this publication may be reproduced in any format without written consent of EB Practice, LLC. Subscription price: \$299, U.S. funds. (Call for international shipping prices.)